

Recurrent mobile bearing dislocation after minimally invasive unicompartmental knee arthroplasty

J.R. Anciano Granadillo¹, R.L. Worland², A. Cañellas Trobat¹

1- Servicio de Cirugía Ortopédica y Traumatología. Hospital General Mateu Orfila. Mahón

2- Advanced H. Orthopaedic Center. Richmond, Virginia. EEUU

Abstract

Over the last three decades, unicompartmental knee arthroplasty (UKA) has varied in its popularity. More recently the minimally invasive technique with improved instrumentation has resulted in a strong resurgence of interest in unicompartmental arthroplasty. Either in long term or short ones, UKA has shown excellent results specially if the surgeon follows the very delicate criteria for case selection. Even though it is a very demanding technique, the indications for UKA have expanded and only time will allow us to evaluate these changes.

There is a significant learning curve in performing UKA through the minimally invasive technique. We report a case of recurrent dislocation of a mobile bearing polyethylene insert which required conversion to a total knee arthroplasty.

Keywords: unicompartmental knee arthroplasty, minimally invasive technique, recurrent dislocation, total knee arthroplasty.

Resumen

Transcurridas las últimas tres décadas, la artroplastia unicameral de rodilla (AUR) ha variado en popularidad y aceptación. Recientemente, la técnica miniinvasiva con el avance de la nueva instrumentación, han logrado una fuerte reaparición en el interés de la artroplastia unicompartmental. Ya en largas o breves series, la AUR presenta excelentes resultados en especial si, el cirujano sigue escrupulosamente los criterios de selección de casos. Las indicaciones para la AUR han sido ampliadas y, únicamente el tiempo nos facilitará el poder evaluar estas variaciones.

Hay una notoria curva de aprendizaje en la ejecución de la AUR a través de la técnica miniinvasiva. Presentamos un caso de luxación recurrente de un platillo meniscal de polietileno móvil implantado, que precisó un recambio a una prótesis total de rodilla.

Palabras clave: prótesis unicameral de rodilla, técnica miniinvasiva, luxación recurrente, prótesis total rodilla.

Correspondencia

A. Cañellas Trobat · Hospital General Mateu Orfila · Avda. Ronda s/n, Malbuger · 07701 · Mahón · Menorca

Introduction

Today, UKA is reported to be an appropriate option for patients with anteromedial knee arthritis leading to significant pain relief, restoration of range of motion, a better quality of life with less bone loss and no risk of transfusion with surgery compared to total knee arthroplasty. Ten and fifteen years follow-up studies with UKA have provided excellent results if the surgery is carried out in the appropriate patient utilizing the strict surgical technique (1,2,3,12,13,17,18).

Multiple studies have shown that the minimally invasive approach leads to the above findings with a brief stay in hospital as well as faster rehabilitation and near normal ambulation, accredited by different studies in the mid and long term results (4,5,6,7,8,9).

As the popularity of UKA has increased, so have the complications: tibial fractures, breakage and wearing of the polyethylene, progression of pain and osteoarthritis as well as dislocation of mobile polyethylene bearings (6,7,18).

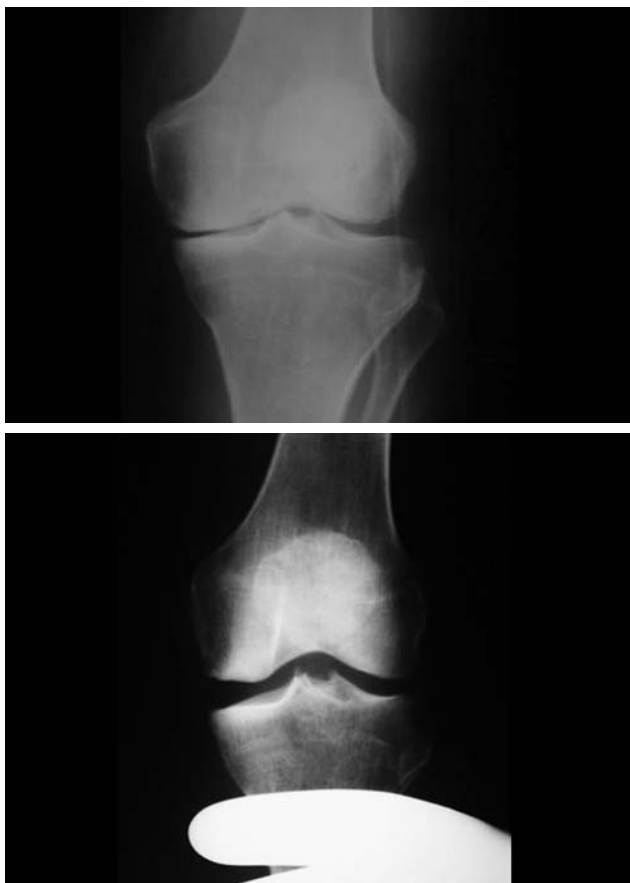


Fig. 1 a-b.- Osteoarthritis of medial compartment with the subchondral bone narrow. Functional passive valgus and with a safe lateral space

Given that we believe that UKA is a successful procedure, we accept it is also a very demanding one with a learning curve in which every step of the procedure has to be done meticulously. We report a typical case of anteromedial arthritis that matched all the criteria for UKA but the results were not the expected.

Case Report

A 74 year-old retired NASCAR pit crew chief, not very active, had right knee pain for many years, a very tender medial compartment, a complete extension and flexion more than 120°. His scanogram revealed that he was in 13 degrees of varus and, the diagnose with isolated anteromedial compartmental left knee osteoarthritis. His deformity was passively correctable on valgus stress X-rays, and there was no narrowing of the lateral compartment suggesting that he was a perfect candidate (fig.1).

He underwent a minimally invasive UKA with the Oxford unicompartmental Knee (BIOMET, UK) on

2004(fig. 2a). A medium femoral component was utilized and the tibial base plate and femoral component were cemented. A 5 mm medium insert was snapped into place and it moved appropriately in an anterior direction with extension and posteriorly with flexion. By 2 weeks after surgery and he had made an excellent recovery with essentially no pain and full range of motion. X-rays were ideal (fig.2b).

Two months later the patient returned to the office with excruciating pain unable to bear weight. X-rays revealed a posterior dislocation of the mobile bearing (fig.3).

At the time of surgery a 6 mm bearing was inserted but we couldn't find the first one. One more time it worked perfect under direct visualization with maximum extension and flexion and he initially did very well. The new insert was in the right position. The posteriorly displaced bearing could not be retrieved and was left where it was.

One month later he returned with pain in the knee and the tibial bearing had slid to a somewhat posterior position.

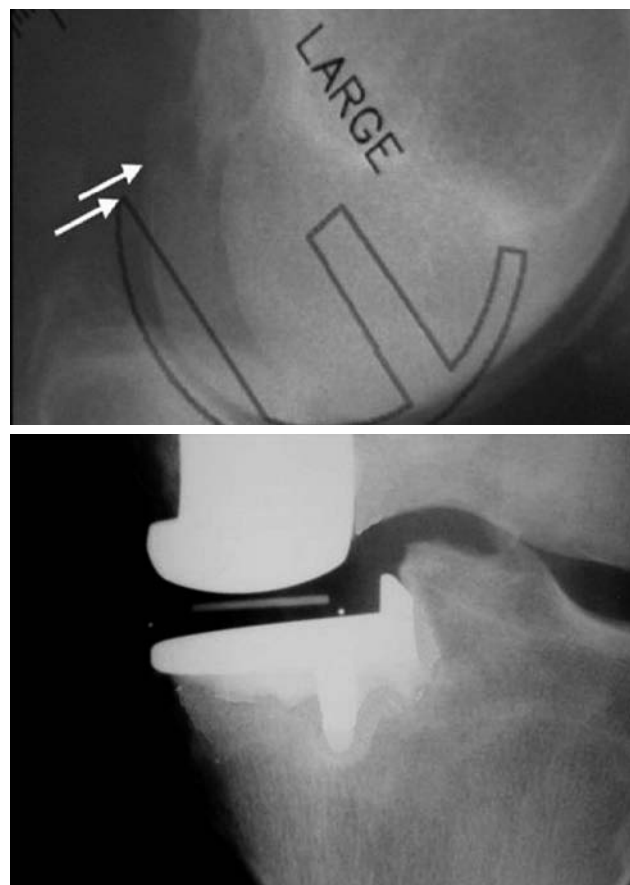


Fig. 2 a-b.- Tray to size mark of the femoral implant. The AP radiograph with the medial unicompartmental prosthesis implanted.

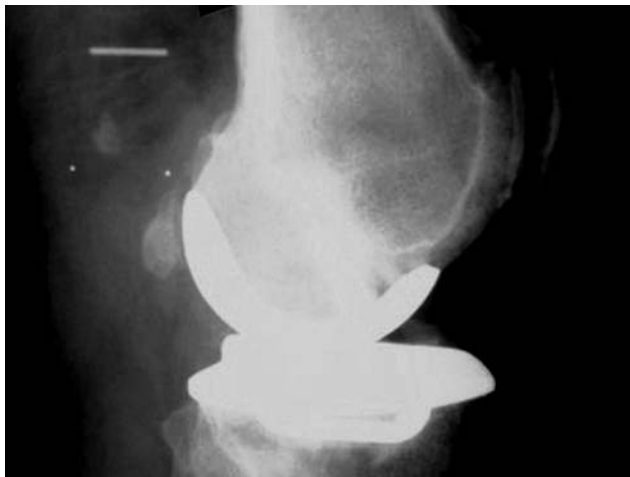

Fig. 3.- Lateral radiograph shown a posterior dislocation of the meniscal bearing PE implant

He was taken to the operating room and his unicompartmental knee was revised to a primary total knee arthroplasty (AGC Knee, BIOMET)(fig.4).

Four years and six months total knee follow-up, the patient is doing perfect, had full motion with no pain and a knee score of 90 points.

Discussion

Dislocation of mobile polyethylene bearings has been described as a complication of UKA it has a 10% dislocation rate and, is most commonly seen on the lateral side (2,8,14,15,16,18). In this case the dislocation was posterior and cephalad into the popliteal space fossa.

Since, the first polyethylene was not given symptoms and we couldn't find it during the TKA, we decided to leave it there, avoiding more risk procedures and trauma to the knee.

A second dislocation occurred after the first, which led to conversion to a total knee arthroplasty. We believe the reason for this bearing dislocation to be that the sagittal cut for the tibial base plate was too far lateral, allowing enough space for the bearing to spin 90 degrees and then dislocate posteriorly. New longer bearings have been developed which prevent spinning and dislocation.

What called our attention of this case was that the UKA worked well during the surgery and the first weeks, and suddenly it dislocated. We didn't want to convert to a TKA in the first place, because we

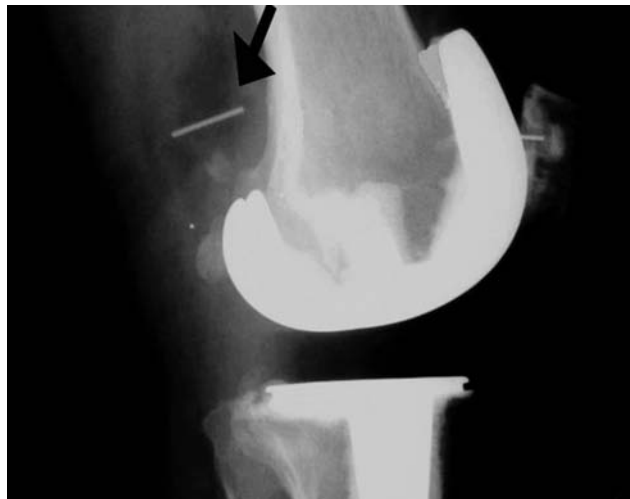

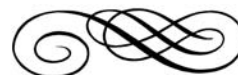Fig. 4.- Leaved in the popliteal fossa, see the arrow, and replacement for total cemented arthroplasty prosthesis.

though that changing to a bigger polyethylene could solve the problem, but it didn't. So, the only possible solution was the TKA. UKA is a very successful procedure with success rates of 98% to 99% at 10 years (1,2,3,12,13). As the dislocated bearing was inaccessible, it was left in place. Conversion to a total knee arthroplasty should have been done following the first dislocation and placement of a thicker bearing in most cases is probably not the proper solution.

Conclusion

We believe that UKA is a demanding procedure, with specific indications and a significant learning curve to achieve good results. Today that technique is even more demanding if it is combined with minimal invasive technique, will permit faster healing, with less blood loss, less bone lost and a more rapid recovery for the patient.

Even when we are doing minimal invasive technique for UKA, we agree that the former has not been well documented for the long terms results as a procedure but, it certainly make the UKA more difficult to achieve, given less space to mark, to see and to maneuver. Leading these to an increase percentage of errors and complications. Once mastered, the minimally invasive approach for UKA is not associated with a significant complication rate.



References

1. Murray DW, O'Connor JJ, Goodfellow JW. The Oxford medial unicompartmental arthroplasty, a ten year survival study. *J Bone Joint Surg (Br)*1998;80-B(6):983-9.
2. Price A, Svard U, Murray DW, Goodfellow JW. Ten year survival results of Oxford mobile bearing unicompartmental knee arthroplasty in young patients. I.S.T.A. Chicago. 1999.
3. Keys GW, Carr AJ, Miller RK, Goodfellow J. The radiographic classification of medial gonarthrosis. Correlation with operative methods in 200 Knees. *Acta Orthop Scand* 1992;63(5):497-01.
4. Kuag-Ying Y, Seng-Jin Y, Ngai-Nung L. Stress fracture of the medial tibial plateau after minimally invasive unicompartmental knee arthroplasty. *J. Arthroplasty.* 2003;18(6):801-3.
5. Kelly GV, Leoh TC. Unicompartmental knee arthroplasty. New indications, more complications?. *J. Arthroplasty.* 2004;Vol.19(4) Suppl 1:9-16.
6. Price AJ, Webb J, Top H, et al: Rapid recovery after Oxford unicompartmental arthroplasty through a short incision. *J. Arthroplasty.* 2001;16:970.
7. Jean-Noel AA, Chevrol-BenKeddache Y, Aubaniac JM. Modern unicompartmental knee arthroplasty with cement. A three to ten-year follow-up study. *J. Bone Joint Surg. Am.* 2002; 84-A(12):2235-9.
8. Romanowski MR, Repicci JA. Minimally invasive unicompartmental arthroplasty: eight-year follow-up. *J Knee Surg. Am.* 2002;15:17.
9. Marmor L. Unicompartmental knee arthroplasty. Ten to 13 year follow-up study. *Clin. Orthop.*1998;226:14-20.
10. Howe DJ, Taunton OD Jr., Engh GA. Retained cement after unicompartmental knee arthroplasty. A report of four cases. *J Bone Joint Surg. Am.*2004; 86A(10):2283-6.
11. Robinson BJ, Rees JL, Price AJ, et al. Dislocation of the bearing of the Oxford lateral unicompartmental arthroplasty: a radiological assessment. *J Bone Joint Surg. Br.* 2002;84:653-6.
12. Robertson O., Knutson K., Lewold S., Lidgren L. The routine of surgical management reduces failure after unicompartmental knee arthroplasty. *J Bone Joint Surg. Br.* 2001;83(1):45-9.
13. Insall J., Aglietti P. A five to seven-year follow-up of unicompartmental arthroplasty. *J Bone Joint Surg. Am.* 1980;62(8):1329-37.
14. Verhaven E, Handelberg F, Casteleyn PP, Opdecam P. Meniscal bearing dislocation in the Oxford knee. *Acta Orthop. Belg.* 1991;57(4):430-2.
15. Van Tienen TG, Taylor SJ, Brink RB. Successful salvage of a recurrently dislocating Oxford medial unicompartmental bearing. Case report. *J Arthroplasty.* 2010;25(3):497-9.
16. Song MH, Kim BH, Ahn SJ, Yoo SH, Lee MS. Early complications after minimally invasive mobile-bearing medial unicompartmental knee arthroplasty. *J. Arthroplasty.* 2009;24(8):1281-4.
17. Goodfellow JW, O'Connor JJ. Clinical results of the Oxford knee. *Clin.Orthop.*1986;205:21-42.
18. Goodfellow JW, Kershaw CJ, Benson MK, O'Connor JJ. The Oxford knee for unicompartmental osteoarthritis. *J. Bone Joint Surg.* 1988; 70B:692-01.