

## CASE REPORT

# An unexpected cause of delirium: severe hypercalcemia due to primary hyperparathyroidism. A case report

*Una causa inesperada de delirio: hipercalcemia grave debida a hiperparatiroidismo primario. Informe de un caso*

**Antelm Pujol<sup>1</sup>** , **Luis Alberto Gómez<sup>1</sup>**, **Rosmeri Rivera<sup>1</sup>**, **Regina Fortuny<sup>2</sup>**, **Guido Sfondrini<sup>1</sup>**, **Lluís Masmiquel<sup>1</sup>** 

1. Endocrinology and Nutrition Department, Son Llàtzer University Hospital. Health Research Institute of the Balearic Islands (IdISBa).

2. Laboratory Department, Son Llàtzer University Hospital, Health Research Institute of the Balearic Islands (IdISBa).

Palma de Mallorca, Balears, Spain.

**Corresponding author**

Antelm Pujol

E-mail: antelm.pujol@gmail.com

**Received:** 24 - IV - 2023

**Accepted:** 25 - V - 2023

**doi:** 10.3306/AJHS.2023.38.05.166

## Abstract

Acute confusional syndrome (ACS) or delirium is a frequent reason for emergency department consultation in elderly people. Moderate-severe hypercalcemia secondary to primary hyperparathyroidism is not a typical or frequent presentation of ACS. Serum calcium levels would be proportional to the severity of neuropsychiatric symptomatology. Normalization of calcium levels should lead to the reversibility of the symptomatology. However, case series of primary hyperparathyroidism report a high prevalence of neuropsychiatric symptoms in these patients, and it is hypothesized that these symptoms may be underreported in the scientific literature. We present the case of a 79-year-old woman with a diagnosis of ACS as a result of severe hypercalcemia secondary to primary hyperparathyroidism due to parathyroid adenoma.

**Key words:** delirium, hypercalcemia, hyperparathyroidism, parathyroid adenoma.

## Resumen

El síndrome confusional agudo (SCA) o delirium es un motivo frecuente de consulta en urgencias en ancianos. La hipercalcemia moderada-grave secundaria a hiperparatiroidismo primario no es una presentación típica o frecuente de SCA. Los niveles séricos de calcio serían proporcionales a la gravedad de la sintomatología neuropsiquiátrica. La normalización de los niveles de calcio debería conducir a la reversibilidad de la sintomatología. Sin embargo, las series de casos de hiperparatiroidismo primario informan de una alta prevalencia de síntomas neuropsiquiátricos en estos pacientes, y se plantea la hipótesis de que estos síntomas pueden estar infradeclarados en la literatura científica. Presentamos el caso de una mujer de 79 años con diagnóstico de SCA como consecuencia de hipercalcemia grave secundaria a hiperparatiroidismo primario por adenoma paratiroideo.

**Palabras clave:** delirio, hipercalcemia, hiperparatiroidismo, adenoma paratiroideo.

## Introduction

ACS or delirium is defined as an acute change in alertness, attention, and cognition, and it is caused by a medical condition excluding the pre-existence of a previous neurocognitive disorder<sup>1</sup>. There are predisposing factors for the onset of the condition, principally advanced age, as well as acute or triggering factors. Among the latter, infections, drug intoxication, glucose metabolism alterations, and ionic alterations are the most frequent causes<sup>2</sup>. Fifty percent of the causes of delirium are reversible.

Calcium plays a role in the metabolism of monoamines at the cerebral level, which explains how calcium alterations can produce psychological/psychiatric symptomatology<sup>3</sup>. Primary hyperparathyroidism is the most frequent cause of hypercalcemia. However, in most cases, this entity is asymptomatic<sup>4</sup>. In fact, in 1964, Agras et al.<sup>5</sup> postulated that only 4.6% of primary hyperparathyroidism cases caused delirium. Although there are published cases of ACS caused by moderate-severe hypercalcemia secondary to primary hyperparathyroidism, this is not a typical nor frequent presentation<sup>5</sup>. Serum calcium levels would be proportional to the severity of neurological symptoms<sup>5</sup>.

There is a strong probability that the normalization of calcium levels resolves the acute clinical situation, but psychiatric symptoms such as depression, apathy, and irritability may persist even with calcium levels between 10-14 mg/dL<sup>5</sup>. Psychiatric symptoms are not included in the surgical criteria for primary hyperparathyroidism, despite the fact that some studies show significant improvements after a surgical approach is followed with respect to these patients<sup>6-9</sup>.

In this report, we describe a clinical case where ACS was the initial presentation for a diagnosis of primary hyperparathyroidism.

## Case report

A 79-year-old Caucasian woman with a relevant history of arterial hypertension, dyslipidemia, anxious depressive syndrome receiving treatment regularly with lercanidipine 20mg/day, chlorthalidone 50mg/day, tramadol/paracetamol 75mg/650mg and escitalopram 15mg/day was brought to the emergency department by her daughter, after two days of bradypsychia, disorientation,

and significant functional impairments. She had been leading an active life up to this point, with neither cognitive nor physical limitations. No other clinical signs by apparatus or systems were reported. On physical examination, the palpation of a nodule of homogeneous consistency in the anterior-cervical region, at the inferior level of the left thyroid lobe, stood out. The rest of the physical examination showed results within the normal range.

However, in the analysis in the emergency room, severe hypercalcemia 15.80 mg/dL (8.80-10.20mg/dL), mild hypophosphatemia 2.10 mg/dL (2.30 - 4.70mg/dL), and mild hypomagnesemia 1.30 mg/dL (1.60-2.60 mg/dL) were observed. Renal function, together with the rest of the laboratory tests resulted normal. An electrocardiographic study was performed and chest and lumbar radiographs were anodyne.

Intensive fluid therapy with saline, calcitonin, and a dose of zoledronic acid was administered. During her stay in the hospital, the case was studied and the ionic disbalances were corrected. Complementary tests were requested and the patient's previous medical history was reviewed.

- Laboratory tests on admission: severe hypercalcemia 15.80 mg/dL (8.80-10.20 mg/dL), mild hypophosphatemia 2.10 mg/dL (2.30-4.70 mg/dL), and mild hypomagnesemia 1.30 mg/dL (1.60-2.60 mg/dL) secondary to hyperparathyroidism. Parathyroid hormone levels were 470.70 pg./mL (15-68 pg./mL) with slightly decreased vitamin D levels 19.90 ng/mL (30-50 ng/mL).
- Daily ionic control: serum calcium levels are monitored with the pertinent therapeutic adjustment (see **table I**).
- Ultrasound of the abdomen showed non-obstructive lithiasis in both kidneys. Cholecystectomy (see **image 1**).

Image 1: Abdominal ultrasound.

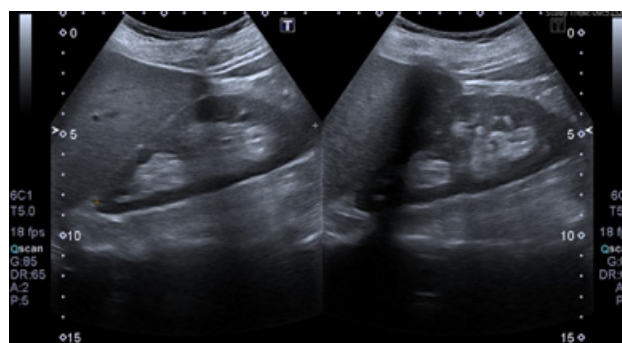
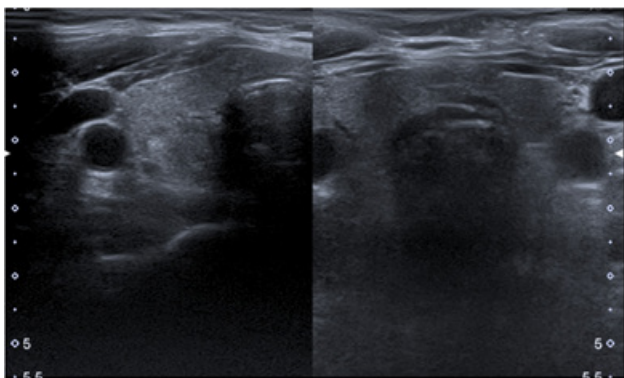


Table I: daily ionic monitoring evolution.

	Day 1	Day 2	Day 3	Day 4	Day 5	Day 6	Day 7
Calcium (8.80-10.20 mg/dL)	15.80	13.70	12.10	11.0	10.20	9.80	9.40
Phopspante (2.30-4.70 mg/dL)	2.10	1.30	1.10	1.40	1.60	2.40	2.60
Magnesium (1.60-2.60 mg/dL)	1.20	1.35	1.80	1.94	2.10	2.30	2.41
Sodium (136-145 mmol/L)	141.3	143.2	137.0	139.1	138.3	137.7	138.1
Potassium (3.6-5.3 mmol/L)	3.12	3.05	3.30	3.53	3.80	3.83	4.65

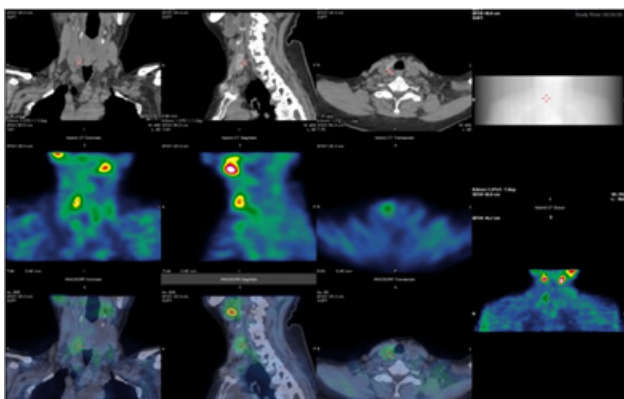
- 24-hour urine: Correct urine collection with a calculated glomerular filtration rate of 85 mL/min, calcium 145.20 mg/24h (100-300 mg/24h), phosphate 488.40 mg/24h (400-1200mg/24h), magnesium 130.68 mg/24h (73-122mg/24h), sodium 231mg/24h (40-220mg/24h) and potassium 58mg/24h (25-125mg/24h).
- Thyroid ultrasound: Thyroid of normal size, morphology, and echogenicity, with no evidence of nodular images. No images suggestive of pathology were identified in the parathyroid areas. No latero-cervical adenopathies of any significant size are observed (see **image 2**).

**Image 2:** Thyroid ultrasound.



- <sup>99m</sup>Tc-sestamibi scintigraphy (administered dose of 20,0 mCi): Overactive nodular lesion of 13x10mm located at posterior and superior region of the right thyroid lobule (see **image 3**).

**Image 3:** <sup>99m</sup>Tc-sestamibi scintigraphy showing an overactive nodule at posterior and superior region of the right thyroid lobule.



- Medical history review: The previous blood test prior to admission was 14 months before and showed normal levels of calcium in the blood. An ultrasound of the abdomen 12 years prior to admission showed renal lithiasis.

The case was diagnosed as an acute confusional syndrome, resulting from severe hypercalcemia, secondary to primary hyperparathyroidism due to parathyroid adenoma.

Along with the gradual improvement of blood calcium levels and the previously mentioned diagnosis, calcimimetics (cinacalcet) were introduced, achieving not only normalization of calcemia, but also a clear and sustained improvement of the acute confusional syndrome with which she was admitted. Gradually, the patient recovered orientation and higher functions prior to baseline according to herself and her daughter (her main caregiver). She was discharged with stable blood calcium levels, adjusted treatment, interconsultation for preferential surgery, and follow-up at Endocrinology and Nutrition outpatient clinics. The first appointment was made a week later in our offices with stable calcemia at 8.90mg/dL (8.80-10.20 mg/dL), stable with cinacalcet at a dose of 60mg every 24 hours.

## Discussion

We describe a case of acute confusional syndrome as the first manifestation of severe hypercalcemia, secondary to primary hyperparathyroidism due to parathyroid adenoma. By means of pharmacological treatment, calcium levels were reduced with a clear improvement in neuropsychiatric symptoms. The patient meets the criteria for surgical management (non-urgent) for removal of the parathyroid adenoma<sup>10</sup>.

Cases of acute confusional syndrome due to primary hyperparathyroidism have been reported in the literature for more than 50 years<sup>11</sup>. Park et al<sup>5</sup> attribute the severity of neuropsychiatric symptoms to plasma calcium levels. In fact, moderate hypercalcemia (10-14mg/dL) is associated with depression, apathy, and irritability. Severe hypercalcemia (>15mg/dL), as in the presented case, could therefore cause acute confusional syndrome with or without psychotic symptoms, catatonia, and even lethargy<sup>5</sup>. Normalization of calcium levels would lead to the reversibility of the symptomatology. Many of the cases described in the literature make use of an urgent surgical approach for the management of these patients and report good results<sup>6-9</sup>.

Rao et al<sup>12</sup> performed a randomized clinical trial in asymptomatic primary hyperparathyroidism patients with normal or slightly elevated calcemia (10.1 to 11.5 mg/dL), with PTH higher than 20pg/mL, normal renal function, and absence of complications and relevant symptoms. Patients were divided into two groups: one group was managed conservatively, and the other group underwent total parathyroidectomy. People who underwent total parathyroidectomy showed a decrease in suicidal ideation from 22% to 10.7%, a decrease in anxiety from 49% to

22.4%, and a decrease in depression from 16.6% to 6.6%<sup>12</sup>. This is not the only study reporting these results. Weber et al (9) et al 2007 performed a case-control trial on neuropsychological symptoms in patients with primary hyperparathyroidism who were going to undergo total parathyroidectomy. 66 patients were evaluated both pre- and post-surgery using validated tests (HADS, PHQ-9 and SF-12). Preoperative depressive symptoms were present in 23.4% of patients and 15.6% had anxiety symptoms. The surgical approach achieved a significant reduction in prevalence: 7.8% and 15.7%, respectively. It should be noted that the prevalence of depression before surgery was higher in subjects with calcium levels above 11.2mg/dL.

In fact, some authors claim that neuropsychiatric symptomatology in patients with primary hyperparathyroidism could be underreported, especially in the older population<sup>5,13</sup>. Neuropsychiatric symptomatology in some series of patients undergoing parathyroidectomy would have a prevalence of 43.1% to 53% for anxiety, 33-62.1% for depression, 22% for suicidal ideation, 51.9% for irritability, 5% to 20% for hallucinations and 37.3% to 46.5% for cognitive impairment<sup>5,6,14,15</sup>.

In the scientific literature, we have not found data comparing pharmacological management to surgical management in neuropsychiatric symptomatology caused by hypercalcemia secondary to primary hyperparathyroidism.

## Conclusions

- Alterations in calcium metabolism can be associated with neuropsychiatric symptoms, the severity of which is potentially proportional to the severity of the ionic alteration.
- Neuropsychiatric symptomatology may be underreported in the scientific literature in patients with primary hyperparathyroidism.
- The high prevalence of these symptoms and the clear improvement reported by the surgical approach could support the inclusion of neuropsychiatric symptomatology within the surgical criteria for primary hyperparathyroidism.

## Conflict of interest

The authors declare no conflict of interest.

## Bibliography

1. Wilson JE, Mart MF, Cunningham C, Shehabi Y, Girard TD, MacLulich AMJ, et al. Delirium. *Nat Rev Dis Primer*. 2020 Nov 12;6(1):90.
2. Inouye SK, Westendorp RGJ, Saczynski JS. Delirium in elderly people. *Lancet Lond Engl*. 2014 Mar 8;383(9920):911-22.
3. Papa A, Bononi F, Sciubba S, Ursella S, Gentiloni-Silveri N. Primary hyperparathyroidism: acute paranoid psychosis. *Am J Emerg Med*. 2003 May;21(3):250-1.
4. MacKenzie-Feder J, Sirrs S, Anderson D, Sharif J, Khan A. Primary Hyperparathyroidism: An Overview. *Int J Endocrinol*. 2011;2011:251410.
5. Parks KA, Parks CG, Onwuameze OE, Shrestha S. Psychiatric Complications of Primary Hyperparathyroidism and Mild Hypercalcemia. *Am J Psychiatry*. 2017 Jul 1;174(7):620-2.
6. Zanocco K, Butt Z, Kaltman D, Elaraj D, Cella D, Holl JL, et al. Improvement in patient-reported physical and mental health after parathyroidectomy for primary hyperparathyroidism. *Surgery*. 2015 Sep;158(3):837-45.
7. Espiritu RP, Kearns AE, Vickers KS, Grant C, Ryu E, Wermers RA. Depression in primary hyperparathyroidism: prevalence and benefit of surgery. *J Clin Endocrinol Metab*. 2011 Nov;96(11):E1737-45.
8. Rosenthal M, Gil I, Habet B. Primary hyperparathyroidism: neuropsychiatric manifestations and case report. *Isr J Psychiatry Relat Sci*. 1997;34(2):122-5.
9. Weber T, Keller M, Hense I, Pietsch A, Hinz U, Schilling T, et al. Effect of parathyroidectomy on quality of life and neuropsychological symptoms in primary hyperparathyroidism. *World J Surg*. 2007 Jun;31(6):1202-9.
10. Wilhelm SM, Wang TS, Ruan DT, Lee JA, Asa SL, Duh QY, et al. The American Association of Endocrine Surgeons Guidelines for Definitive Management of Primary Hyperparathyroidism. *JAMA Surg*. 2016 Oct 1;151(10):959-68.
11. Kleinfeld M, Peter S, Gilbert GM. Delirium as the predominant manifestation of hyperparathyroidism: reversal after parathyroidectomy. *J Am Geriatr Soc*. 1984 Sep;32(9):689-90.
12. Rao DS, Phillips ER, Divine GW, Talpos GB. Randomized controlled clinical trial of surgery versus no surgery in patients with mild asymptomatic primary hyperparathyroidism. *J Clin Endocrinol Metab*. 2004 Nov;89(11):5415-22.
13. Perrier ND. Asymptomatic hyperparathyroidism: a medical misnomer? *Surgery*. 2005 Feb;137(2):127-31.
14. Joborn C, Hetta J, Lind L, Rastad J, Akerström G, Ljunghall S. Self-rated psychiatric symptoms in patients operated on because of primary hyperparathyroidism and in patients with long-standing mild hypercalcemia. *Surgery*. 1989 Jan;105(1):72-8.
15. Liu JY, Saunders ND, Chen A, Weber CJ, Sharma J. Neuropsychological Changes in Primary Hyperparathyroidism after Parathyroidectomy. *Am Surg*. 2016 Sep;82(9):839-45.