

## CASE REPORT

# Surgical treatment of a patient with hemangiopericytoma and subsequent abdominoplasty: a clinical case

*Tratamiento quirúrgico de una paciente con hemangiopericitoma y posterior abdominoplastia: un caso clínico*

**Alexey V. Shabunin<sup>1,2,3</sup>** , **David D. Dolidze<sup>1,2,3</sup>** , **Ivan N. Lebedinsky<sup>1,3</sup>** ,  
**Zurab A. Bagatelia<sup>1,2,3</sup>** , **Anna S. Sukhotko<sup>3</sup>** , **Maria V. Kovaleva<sup>2</sup>** , **Serghei Covantsev<sup>1</sup>** 

1. Department of Clinical Research and Development, Botkin Hospital, Moscow, Russian Federation

2. Department of Surgery, Russian Medical Academy of Continuous Professional Education, Moscow, Russian Federation

3. Department of General Oncology No 71, Botkin Hospital, Moscow, Russian Federation

**Corresponding author**

Serghei Covantsev

E-mail: kovantsev.s.d@gmail.com

**Received:** 25 - II - 2023

**Accepted:** 20 - IV - 2023

**doi:** 10.3306/AJHS.2023.38.04.166

## Abstract

Hemangiopericytoma is a rare neoplasm of mesenchymal tissue, which is mentioned in the literature mainly in the form of clinical observations. The tumor usually occurs at the age of 20-70 years in the soft tissues of the neck, lower extremities, retroperitoneal space and pelvis. There have been only 20 cases of hemangiopericytoma of the anterior abdominal wall. In rare cases they are associated with paraneoplastic syndromes. In the presented clinical observation, the patient underwent a wide excision of soft tissue tumor, initially regarded as a desmoid, followed by abdominoplasty. The combination of wide excision with abdominoplasty leads an optimal cosmetic result while not violating oncological principles.

**Keywords:** desmoid tumor, hemangiopericytoma, wide excision, abdominoplasty.

## Resumen

El hemangiopericitoma es una neoplasia poco frecuente del tejido mesenquimal, que se menciona en la literatura principalmente en forma de observaciones clínicas. El tumor suele aparecer entre los 20 y los 70 años de edad en los tejidos blandos del cuello, las extremidades inferiores, el espacio retroperitoneal y la pelvis. Sólo se han registrado 20 casos de hemangiopericitoma de la pared abdominal anterior. En raras ocasiones se asocian a síndromes paraneoplásicos. En la observación clínica presentada, la paciente fue sometida a una escisión amplia del tumor de partes blandas, considerado inicialmente como un desmoide, seguida de abdominoplastia. La combinación de escisión amplia con abdominoplastia conduce a un resultado cosmético óptimo sin violar los principios oncológicos.

**Palabras clave:** tumor desmoide, hemangiopericitoma, escisión amplia, abdominoplastia.

## Introduction

Hemangiopericytomas are abundantly vascularized mesenchymal tissue tumors that are currently classified as solitary fibrous tumors. They were first described by Stout and Murray in 1942 as a group of vascular tumors derived from Zimmerman's pericytes<sup>1,2</sup>. Depending on the cellular composition, they are classified as hemangiopericytomas if the cellular component predominates and solitary fibrous tumors if the hyalinizing form of neoplasia predominates. Most commonly, this tumor occurs in the neck, meninges, pleura, retroperitoneum, pelvis, and lower extremities<sup>3</sup>. The incidence is 0.06 per 100,000 examined, and localization within the abdominal wall

has been described in only 20 cases<sup>3-5</sup>. There are two types of tumor: malignant and benign; in turn, the latter can become malignant over time. Due to the rare occurrence of the disease and the diverse localization, there are currently no precise recommendations on the tactics of treating these patients. Surgical intervention is considered optimal, which, if necessary, is supplemented by subsequent adjuvant chemotherapy or radiotherapy and active monitoring over time. In the presented clinical observation, the patient underwent a wide excision of soft tissue tumor, initially regarded as a desmoid, followed by abdominoplasty.

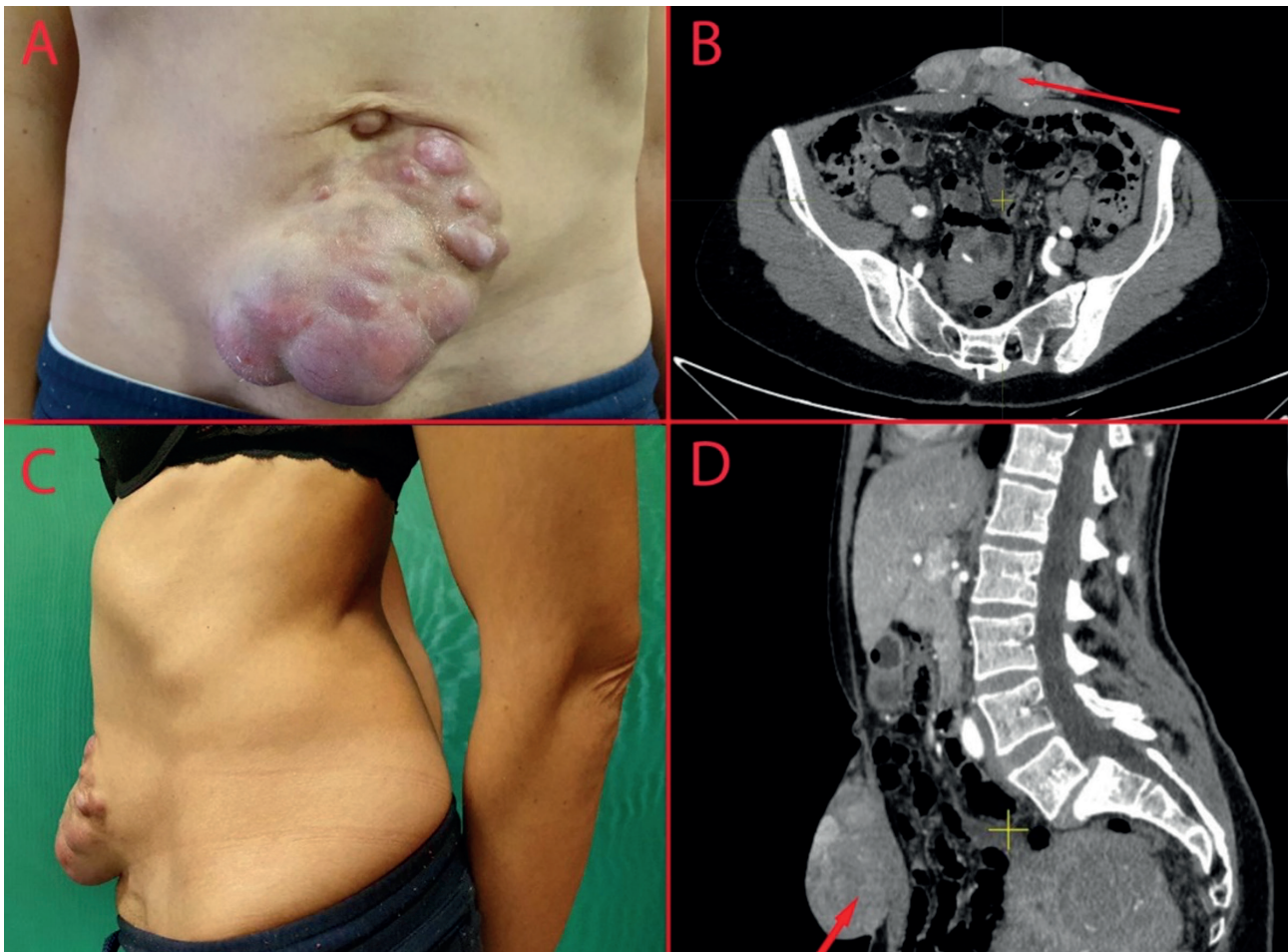
## Clinical case

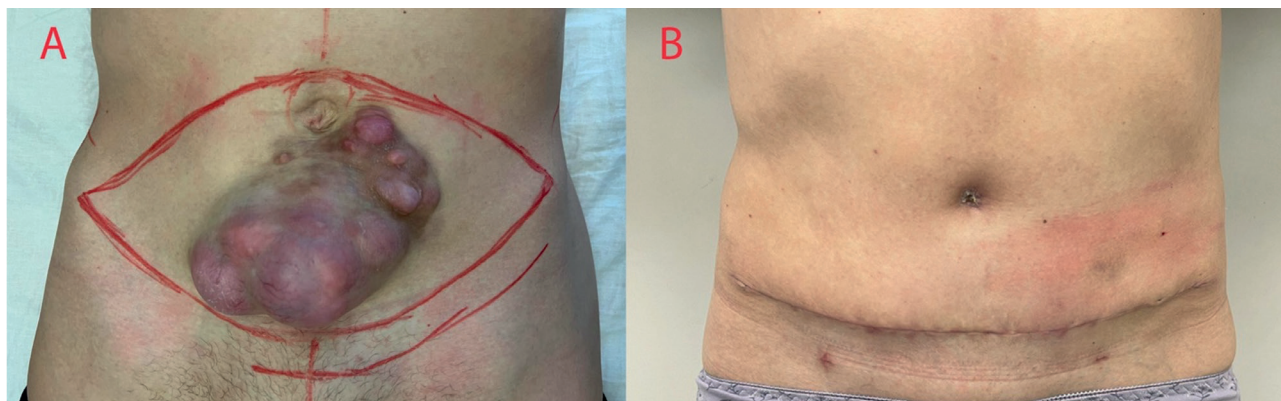
In 2019 a 43 years old woman drew attention to the appearance of a mass of the anterior abdominal wall in the umbilical region. She observed the mass until June 2022 and due to the increase in size the patient consulted a surgeon, then was referred for a consultation to an oncologist. On examination the entire anterior abdominal wall below the umbilicus was represented by a voluminous multinodular mass measuring 18x15 cm with clear, even contours, the skin over the tumor was hyperemic but without changes around the mass (**Figure 1A, 1C**). On palpation, the tumor was painless, it was displaced along with the skin relative to the underlying tissues and the inguinal lymph nodes were not enlarged.

On July 25, 2022, the patient undergone a core-needle biopsy of the lesion. The histological conclusion was desmoid type fibromatosis. Immunohistochemical study revealed that tumor cells were Actin- CD34+ Beta-catenin+. She underwent computed tomography (CT) of the abdominal cavity and pelvis with intravenous contrast enhancement. The CT scan revealed a solid multinodular tumor in the soft tissues of the anterior abdominal wall,

5 mm below the umbilical ring measuring 193x98x42 mm with clear, even contours, most likely originating from the left rectus abdominis muscle and accumulating contrast (**Figure 1B, 1D**). Taking into account the size of the tumor and its location, we decided to perform a wide excision of the mass followed by abdominoplasty. The preoperative marking of the anterior abdominal wall is indicated in **figure 2A**. The patient received preoperative antibiotic prophylaxis with 1 g of cefotaxime 30 minutes before surgery. Surgery was performed under combined endotracheal anesthesia. After preparing the skin with antiseptic solution, the skin and subcutaneous fat were dissected with two incisions. A skin flap with dimensions of 20.0 x 13.0 cm with the mass was isolated up to the fascia. Tumor invasion into the underlying muscles was not detected intraoperatively. The navel was excised and skin flaps were dissected in the cranial direction to the edges of the costal arches and the xiphoid process. The diastasis and the umbilical ring were sutured. The wound was sutured in layers with a cosmetic suture, two vacuum drainages were left, brought out through counter-openings in the region of the inguinal folds.

**Figure 4:** Preoperative picture of the mass. A - anterior projection of the mass B - CT image of the mass (axial section), C - anterior projection of the mass, D - CT image of the mass (sagittal section).



**Figure 2:** Comparison of preoperative and postoperative picture. A - preoperative marking; C - 14th day after the operation.

Umbilicoplasty was performed using the petal method. The patient received symptomatic therapy with NSAIDs in the postoperative period (ketorolac 30 mg intravenously). On the 2nd day after the operation, the drains were removed. At the control ultrasound examination on the 3rd day after the operation there was soft tissue edema in the area of intervention with no fluid accumulations. The patient was discharged from the hospital on the 3rd day after the operation. Histological examination revealed an infiltrative tumor under the epidermis, completely germinating the subcutaneous fat, consisting of long bundles with elongated, thin, spindle-shaped cells of a homogeneous appearance, subcutaneous areas with minimal signs of cellular atypia, rare mitoses. In the deep areas of the tumor there were noticeable cell atypia with mitoses (about 4 per 10 fields of view). Immunohistochemical examination revealed that tumor cells diffusely expressed vimentin, CD34. Ki67 was 2%, beta-catenin and SMA were negative. According to the results of histological and immunohistochemical studies, the mass was classified as hemangiopericytoma. On the 7th and 14th days after the operation, the patient underwent seroma (60 ml) evacuation under ultrasound guidance (**Figure 2A, B**). During a control ultrasound of the soft tissues of the anterior abdominal wall after 12 months there was no data for recurrence.

## Discussions

Hemangiopericytoma is a rare neoplasm of mesenchymal tissue, which is mentioned in the literature mainly in the form of clinical observations. The tumor usually occurs at the age of 20-70 years in the soft tissues of the neck, lower extremities, retroperitoneal space and pelvis. To our knowledge, only 20 cases of hemangiopericytoma of the anterior abdominal wall have been described. According to the literature, most patients were over 50 years old, the average size of the mass was 8 cm (from 1.9 to 16 cm)<sup>1,6,7</sup>. In most cases, patients did not present any complaints, but in some cases they may be bothered by pain or a feeling of pressure in the area of

the tumor<sup>1,8</sup>. In the presented clinical observation, the patient was younger and the tumor was 193 x 98 x 42 mm in size. To our knowledge this is the largest tumor reported in the literature.

Two paraneoplastic syndromes occur in patients with hemangiopericytoma: osteoarthropathy and Doege-Potter syndrome. Hypertrophic arthropathy predominantly occurs in 20% of cases in pleural hemangiopericytomas and is manifested by bone pain, finger clubbing, joint stiffness and swelling. Doege-Potter syndrome occurs in approximately 5% of patients, most often with large tumors localized in the pelvis or retroperitoneum, and manifests itself with hypoglycemia, presumably due to the secretion of IGF-2<sup>9,10</sup>.

An analysis of 1.243 patients with hemangiopericytoma over 41 years indicates that surgery as the main treatment method significantly increases patient survival. At the same time, according to the results of the study, radiotherapy does not affect survival, and chemotherapy reduces it. The combination of various treatment options with surgery, in general, does not improve the prognosis of the disease<sup>3</sup>. A major difficulty in surgery of tumors of the abdominal wall is the surgical intervention, which often leaves an unpleasant and stigmatizing scar. An alternative to only direct excision is subsequent abdominoplasty, as a means to achieve aesthetic results and improve quality of life, while maintaining the standards of surgical oncology.

Histological verification has a number of difficulties and requires immunohistochemical studies. Cells express CD34 antigens in 78-100% of cases, Bcl-2 in 96%, expression of CD99 and vimentin is common. As a rule, cells do not express cytokeratin, actin, desmin, early membrane antigen, c-kit and S100 protein on the surface<sup>1,8,11</sup>.

The question of differential diagnosis of benign and malignant forms of tumors also remains open. To date, there are no precise criteria for malignancy. A presumably high mitosis index, large masses, invasion



into surrounding tissues, the presence of immature cells in the biopsy, necrosis or hemorrhage foci are risk factors for malignancy<sup>3,12</sup>.

Surgical excision with reconstruction using local tissues is a common method for giant tumors<sup>13</sup>. However, the cosmetic results of such procedures is often far from ideal. The current case demonstrates that wide surgical excision of a large tumor with subsequent abdominoplasty is a valid alternative to standard wide excision for larger tumors located in the region of the abdominal wall.

## Conclusion

Hemangiopericytomas are a group of mesenchymal tumors that are most often asymptomatic and difficult to recognize until they cause compression of adjacent structures. In rare cases they are associated with

paraneoplastic syndromes. In the literature, there are only isolated cases of surgical treatment of patients with hemangiopericytomas of the anterior abdominal wall. The combination of wide excision with abdominoplasty leads an optimal cosmetic result while not violating oncological principles.

## Disclosures

Ethics Committee Approval: No ethical approval required and the study was performed in accordance with the principles of the declaration of Helsinki.

## Conflict of Interest

There is no conflict of interest.

## Financial Support

Authors declare that they have not received funds for this study.

## References

1. Migita K, Watanabe A, Nakagawa K, Ohyama T, Sekigawa S. Solitary fibrous tumor of the abdominal wall. *International journal of clinical oncology*. 2009;14(6):555-9.
2. Garcia-Bennett J, Olivé CS, Rivas A, Domínguez-Oronoz R, Huguet P. Soft tissue solitary fibrous tumor. Imaging findings in a series of nine cases. *Skeletal radiology*. 2012;41(11):1427-33.
3. Wang K, Mei F, Wu S, Tan Z. Hemangiopericytoma: Incidence, Treatment, and Prognosis Analysis Based on SEER Database. *BioMed research international*. 2020;2468320.
4. Bi X, Zhai J, Chun CD. Solitary fibrous tumor of the abdominal wall re-surfacing as unilateral pleural effusion and mass: A case report and review of the literature. *Respiratory Medicine Case Reports*. 2018;23:4-7.
5. Testa DC, Selvaggi F, Andreano T, Mazzola L, Cortellese R. Solitary fibrous tumor of the anterior abdominal wall. A case report and review of the literature. *Annali italiani di chirurgia*. 2019;13:8.
6. Carerero Herrera V, Domínguez-Pérez A, González-Martín R, Nacarino-Mejías V, Alcázar Iribarren-Marín M. [Solitary fibrous tumor of the abdomen. A rare neoplasm of vascular origin]. *Gastroenterología y hepatología*. 2010;33(8):578-81.
7. Penel N, Amela EY, Decanter G, Robin YM, Marec-Berard P. Solitary fibrous tumors and so-called hemangiopericytoma. *Sarcoma*. 2012;2012:690251.
8. Costa M, Oliva A, Velez A, Bento A, Garcia H, et al. (2014) Solitary Fibrous Tumor of the Abdominal Wall. *J Clin Case Rep* 4: 363.
9. Yuri T, Kanematsu S, Lei YC, Kuwata M, Oishi M, Tsubura A. Solitary fibrous tumor of soft tissue: a case report and immunohistochemical study. *Medical molecular morphology*. 2010;43(1):60-4.
10. Ouazzani A, Delrée P, De Saint Aubain N, Ceuterick M, Boudaka W. [Malignant solitary fibrous tumor of the abdominal wall in a man]. *Annales de chirurgie plastique et esthétique*. 2008;53(6):517-20.
11. Park MS, Araujo DM. New insights into the hemangiopericytoma/solitary fibrous tumor spectrum of tumors. *Current opinion in oncology*. 2009;21(4):327-31.
12. Enzinger FM, Smith BH. Hemangiopericytoma: An analysis of 106 cases. *Human Pathology*. 1976;7(1):61-82.
13. Shabunin AV, Lebedinsky IN, Dolidze DD, Bagatelia ZA, Covantsev S, Bochamnikov DS, et al. Giant bleeding post-traumatic thoracic sarcoma management: A case report. *Front Surg*. 2022;8:9:1044077.