

Computed tomographic assessment of relationship between renal volume and second vertebral body volume in healthy adult dogs

Evaluación por tomografía computarizada de la relación entre el volumen renal y el volumen del segundo cuerpo vertebral en perros adultos sanos

**Marzieh Yaghmayi¹ , Sarang Soroori² , Hasan Yousefi³ ,
Banafsheh Shateri Amiri² , Yasamin Vali⁴ **

1. Graduate student, Faculty of Veterinary Medicine, University of Semnan, Semnan, Iran

2. Department of Surgery and Radiology Faculty of Veterinary Medicine, University of Tehran, Tehran, Iran

3. Department of Basic Sciences, Faculty of Veterinary Medicine, University of Semnan, Semnan, Iran

4. Diagnostic imaging, Department of Companion Animals and Horses, University of Veterinary Medicine Vienna, Vienna, Austria

Corresponding author

Sarang Soroori
E-mail: Soroori@ut.ac.ir

Received: 1 - IX - 2022

Accepted: 12 - IX - 2022

doi: 10.3306/AJHS.2022.37.06.106

Abstract

Kidney has an important role in controlling hemostasis, therefore pathological changes that affect the size and function of kidneys can alter the normal status of the body. Various diseases alter function and normal anatomical structure of the kidney and increase the total volume of the organ. The object of this study was evaluation of the renal volume relationship to the vertebral body volume of second lumbar vertebra in normal adult dog by means of helical computed tomography and presenting a standard index for evaluating mongrel canine renal volume. In this study, 11 adult mongrel dogs with no sign of renal involvements were entered into the study and the volumes of vertebral body of the second lumbar vertebra were calculated from obtained and reconstructed scans. There was a strong linear association between renal volume and the volume of vertebral body of the second lumbar vertebral ($r^2 \approx 100$). Canine renal volume will change during pathological disease so evaluation of volume can be a good prediction of disease progression. Statistical correlation between renal volume and second vertebral body volume in this study shows the benefit of presenting a standard index for canine renal evaluation by the mean of computed tomography. Findings from this study supported the use of CT renal volumetry in future clinical and research studies.

Key words: Computed tomography, renal volume to vertebral body of the second lumbar vertebral ratio, adult dogs.

Resumen

El riñón tiene un papel importante en el control de la hemostasia, por lo tanto, los cambios patológicos que afectan el tamaño y la función de los riñones pueden alterar el estado normal del cuerpo. Varias enfermedades alteran la función y la estructura anatómica normal del riñón y aumentan el volumen total del órgano. El objetivo de este estudio es evaluar la relación del volumen renal con el volumen del cuerpo vertebral de la segunda vértebra lumbar en un perro adulto normal mediante tomografía computarizada helicoidal y presentar un índice estándar para evaluar el volumen renal de un perro mestizo. En este estudio, se incluyeron 11 perros mestizos adultos sin signos de afectación renal y se calcularon los volúmenes del cuerpo vertebral de la segunda vértebra lumbar mediante los escaneos obtenidos y reconstruidos. Utilizando las pruebas Kolmogorov-Smirnov y Shapiro-Wilk, se evaluó la distribución normal de los datos y hubo una fuerte asociación lineal entre el volumen renal y el volumen del cuerpo vertebral de la segunda vértebra lumbar ($r^2 \approx 100$). El volumen renal del perro cambiará durante la enfermedad patológica, por lo que la evaluación del volumen puede ser una buena predicción del avance de la enfermedad. Correlación estadística entre el volumen renal y el volumen del segundo cuerpo vertebral en este estudio, que son el volumen del riñón derecho y el volumen de L_2 (RKV) = $2.336 + 10.05 L_2V$, El volumen del riñón izquierdo y el volumen de L_2 (LKV) = $1.923 + 10.459 L_2V$, La altura del riñón derecho y la altura de L_2 (RKH) = $-0.544 + 2.592 L_2H$, La altura del riñón izquierdo y la altura de L_2 (LKH) = $0.324 + 2.302 L_2H$, muestra el beneficio de presentar un índice estándar para la evaluación del riñón del perro mediante tomografía computarizada. Los resultados de este estudio apoyaron el uso de la volumetría renal por TC en futuros estudios clínicos y de investigación.

Palabras clave: Tomografía computarizada, la relación del volumen renal con el volumen del cuerpo vertebral de la segunda vértebra lumbar, perros adultos.

Introduction

Kidney has an important role in controlling hemostasis, therefore pathological changes that affect the size and function of kidneys can alter the normal status of the body. Various diseases such as tumors, polycystic kidney disease, hydronephrosis alter function and normal anatomical structure of the kidney and increase the total volume of the organ. There are also other common diseases, including pyelonephritis, interstitial nephritis and glomerulonephritis which increase the total volume of the kidney due to acute inflammatory reactions in early stage of the disease¹. According to Jeon et al. (2012) and Zachary's (2017) studies, the total volume of kidney has a strong correlation with the number of functional nephrons, so if necrosis of the nephrons occurs followed by obstinacy, kidney volume will be decreased^{1,2}. In the study done by Herts et al. (2009), glomerular filtration rate was expressed as the best indicator of renal function. In current study by the creation of a model, estimation of GFR was performed by measuring renal volume and it was shown that kidney volume has significant correlation with GFR. Therefore, kidney volume can be considered as an indicator for determining the normal status of the kidney³. Nephrectomy surgery due to tumor removal is the other factor that can change the kidney volume. Studies about nephrectomy showed correlation between loss of renal function and loss of renal volume after partial nephrectomy for tumors. The existence of this correlation helps surgeons to estimate the volume of the kidney before surgery and to predict the postoperative renal parenchymal volume⁴. Helical computed tomography (sometimes referred to as a spiral) was introduced to diagnostic imaging science in 1990. Multi slice CT is able to scan the entire body due to improved image quality as a result of increasing the spatial resolution, reduced motion artifacts, thin slice and increased color resolution. In this model, while the patient is simultaneously transported into the gantry with the spiral rotation of the tube and detectors, volumetric data is continuously collected at different locations and then reconstruction of images can be provided⁵⁻⁷.

Material and methods

Eleven mixed adult dogs were randomly selected and kept in separate cages for five days in the experimental animals department of the Small Animal Hospital of Tehran University. All of them were fed with commercial foods. After the end of the fifth day, each dog underwent a complete physical examination and full examination of urinary tract including the hydration rate and the presence of ascites and subcutaneous edema, which are symptoms of nephrotic syndrome. Palpation of left kidney (in dog, right kidney is not touchable) was done for evaluation of possible pain,

size and position of the kidney. Blood samples were taken in order to evaluate the cell blood count and differential blood count and biochemical panel. The measurement of serum creatinine and blood urea nitrogen which are known as the most common renal functional tests, were also done. Urine test was performed to examine the appearance, chemical characteristics and presence of possible urine sediment. Finally 11 intact healthy dogs of both sexes were selected. Dogs were placed under anesthesia by intravenous injection of ketamine 10% (5 mg/kg) and diazepam (0.25 mg / kg) after the installation of catheter on the cephalic vein. Dogs were positioned in sternal recumbency, the legs were thoroughly drawn. Plain CT examinations of the kidneys were acquired for each dog (80 mAs, 130 kV, pitch factor of 1mm, and rotation time of 0.8 s). Images were reconstructed at 1-mm for volume estimation using the defined algorithm for the abdomen with Syngo MMWP VE40A software. For contrast, CT examination, Iohexol (Omnipaque® 300 mg/ml) was injected to each dog with dosage of 2 cc/kg body weight and the images were taken after 4 second delay. The kidney volume after the increase of the cortical contrast was measured by the hand tracing option with 1 mm 3D reconstruction, and the volume of the body of the second lumbar spine was also calculated by the same method.

Statistical Analysis

After data gathering, statistical analysis was performed using SPSS 16 software. For the normal index of volume and height of the kidney and second lumbar vertebra, the mean, standard deviation, maximum and minimum of measurements were calculated. By using Kolmogorov-Smirnov and Shapiro-Wilk test, the normal distribution of data was evaluated. Correlation between the volume of the kidney and second lumbar vertebra volume and height were investigated by Pearson method. The linear regression equation was used for evaluation of the relationship between volume of the kidney and the volume and height of second lumbar vertebra.

Results

In this study, the height and volume of 22 healthy kidneys and 11 second lumbar vertebrae were evaluated. Mean, maximum, minimum and standard deviation of each parameter are shown in **table I**.

Table I: Mean, maximum, minimum and standard deviation of each parameter.

| Parameters | N | Min | Max | Mean | SD |
|-----------------------|----|------|--------|---------|----------|
| Right kidney volume | 11 | 1.77 | 103.18 | 37.0618 | 36.82428 |
| Left kidney volume | 11 | 1.92 | 110.61 | 38.0627 | 38.21223 |
| L ₂ volume | 11 | 0.16 | 9.99 | 3.4555 | 3.62002 |
| Right kidney height | 11 | 3.20 | 8.76 | 5.4191 | 1.83132 |
| Left kidney height | 11 | 3.53 | 8.53 | 5.6200 | 1.63459 |
| L ₂ height | 11 | 1.80 | 3.40 | 2.3009 | 0.57185 |

All data were analyzed by Kolmogorov-Smirnov test and Shapiro Wilk test. According to the results of these two tests, which are indicated in **table II**, data were distributed normally.

Table II: Data analysis by Kolmogorov-Smirnov test and Shapiro Wilk test.

| Parameter | Kolmogorov-Smirnov | | | Shapiro-Wilk | | |
|-----------------------|--------------------|----|-------|--------------|----|-------|
| | Statistic | df | Sig. | Statistic | df | Sig. |
| Right kidney volume | 0.250 | 11 | 0.053 | 0.828 | 11 | 0.022 |
| Left kidney volume | 0.244 | 11 | 0.065 | 0.827 | 11 | 0.021 |
| L ₂ volume | 0.298 | 11 | 0.007 | 0.792 | 11 | 0.007 |
| Right kidney height | 0.184 | 11 | 0.200 | 0.922 | 11 | 0.335 |
| Left kidney height | 0.190 | 11 | 0.200 | 0.928 | 11 | 0.390 |
| L ₂ height | 0.274 | 11 | 0.021 | 0.830 | 11 | 0.023 |

There is significant correlation between the volume of the kidney and the volume and height of second lumbar vertebra, which are shown by Pearson correlation coefficient in **table III**.

Table III: Pearson correlation coefficient of data.

| Data | Pearson correlation coefficient |
|---|---------------------------------|
| Volume right kidney and L ₂ | 98.8 |
| Volume of left kidney and L ₂ | 99.1 |
| Height of right kidney and L ₂ | 80.9 |
| Height of left kidney and L ₂ | 80.5 |

According to the **table III**, data have a high correlation coefficient. Regression analysis showed the linear relationship between volume of kidney and the volume and heights of L₂ vertebral body (**Table IV**). These data are demonstrated in **figures 1 to 4** respectively.

Table IV: Linear regression has been used to obtain a correlation between the data.

| Parameter | Equation |
|---|--|
| The right kidney volume and volume of L ₂ | $RKV=2.336+10.05 L_2 V$ |
| The left kidney volume and volume of L ₂ | $LKV=1.923+10.459L_2 V$ |
| The height of right kidney and height of L ₂ | $RKH=-0.544+2.592L_2 H$ |
| The height of left kidney and height of L ₂ | $LKH= 0.324+2.302L_2 H$ |
| RKV: Right kidney volume LKV: Left kidney volume | RKH: Right kidney height LKH: Left kidney height |
| | L ₂ V: Volume of L ₂ L ₂ H: Height of L ₂ |

Discussion

The results of this study showed the relationship between volume and height of second lumbar vertebra with volume of the kidney in computed tomography due to the high breed variation and consequently the difficulty in providing standard indices and, on the other hand, the difference in chest structure and the weight of the animals can provide an important role in assessing the volume of the organs. Vali and Molazem in 2016 announced the relationship between the volume of the kidneys and the volume

Figure 1: Scatter plot showing the linear relationship between the volume of left kidney and the volume of the second lumbar vertebra.

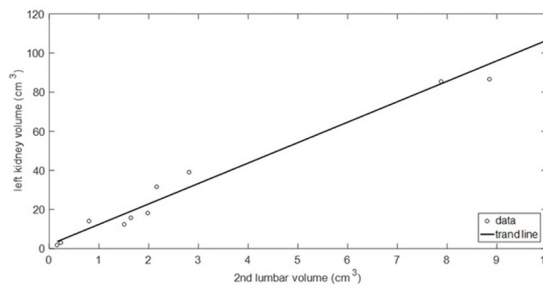


Figure 2: Scatter plot showing the linear relationship between the volume of right kidney and the volume of the second lumbar vertebra.

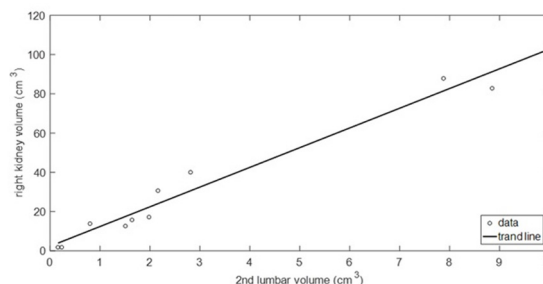


Figure 3: Scatter plot showing the linear relationship between the left kidney height and the height of the second lumbar vertebra.

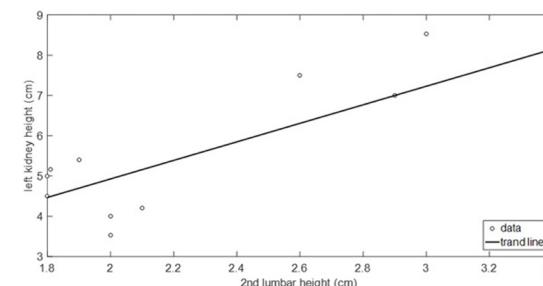
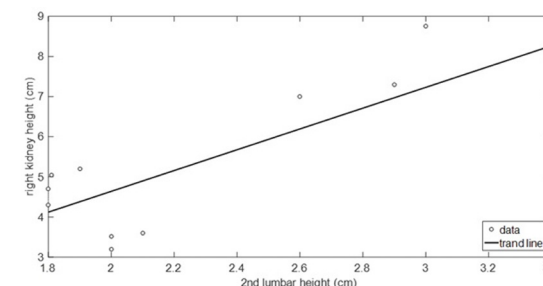


Figure 4: Scatter plot showing the linear relationship between the right kidney height and the height of the second lumbar vertebra.



of the body of the second lumbar spine in a cat, and considered this relationship as an advantage in predicting renal disease⁸. Hoey et al. (2016), measured the height of the kidneys to the height of the second lumbar spine using CT scan, and a significant correlation was reported between them⁹. Due to the variety of diagnostic imaging techniques, in this study, CT scan as a non-invasive diagnostic tool with high precision is proposed as the most accurate volumetric method. Tyson et al., in 2013,

examined two methods of ultrasonography and CT scan with a real measurement method through an autopsy in feline renal volumetric measurement and it was determined that the obtained volume by CT is similar to the actual volume¹⁰. Also, studies on human and animal liver volume have shown that CT scan is the most accurate method of volumetric analysis¹¹⁻¹⁵. In current study, after selecting the best imaging method, manual method of volumetric measurement and 1 millimeter thickness were considered in order to increase the accuracy of measuring the volume of the kidneys and vertebrae in this study. According to the experience of current study and study of Lim et al in 2014 and Sharma et al. in 2015, the freehand scripting approach is a precise method and is useful for measuring kidney volume and excluding vascular structure, urinary collection system and hyper dense cyst, whereas the semi-automated approach yielded somewhat higher parenchymal volume estimates on average. In each instance, the semi-automated approach may occasionally capture other structures such as hilar vessels, or Para pelvic cysts, or a collecting system that may not be segmented out because of similar levels of attenuation. Automatic segmentation is a difficult task because images are often complex and rarely have simple linear features^{11,16}. Lim et al. (2014) believed that there is an inverse relationship between the section thickness and the calculated organs volumes. For this reason, in this study the thickness section was considered as thin as possible¹¹. Based on the study of Lobacz et al. (2012), in the present study, the dogs were adult and one year old. In that study, there was a relationship between age factor and ratio of kidney height

to height of second lumbar spine, so that in dogs below one year, this ratio was larger and no significant changes were observed in dogs over one year¹⁷. According to the study of Vali and Molazem (2016) and our assumption, the weight range was not considered because the second lumbar vertebra can act as an indicator with any weight⁸.

Conclusion

Since the kidneys are considered as vital organs for the body and their volume can be changed due to pathological conditions, and on the other hand, due to the lack of comprehensive studies of volumetric measurement of canine kidney, the assessment of the normal volume of kidneys and presenting standard index aids the technician in determining early treatment. According to the results, a significant correlation was found between the volume of the kidneys and the volume of the second lumbar spine in dogs, suggesting a strong correlation between these two parameters (the volume of right kidney and L_2 , $r = 98.8$), (the volume of left kidney and L_2 , $r = 99.1$).

Acknowledgments

The study was conducted at the Veterinary Teaching Hospital, Department of Surgery and Radiology, Faculty of Veterinary Medicine, University of Tehran, Tehran, Iran.

Conflict of interest statement

The authors declare that they have no conflict of interest.

References

1. Hoey SE, Heder BL, Hetzel SJ, Waller KR 3rd. Use of computed tomography for measurement of kidneys in dogs without renal disease. *J Am Vet Med Assoc.* 2016 Feb 1;248(3):282-7.
2. Jeon HG, Gong IH, Hwang JH, Choi DK, Lee SR, Park DS. Prognostic significance of preoperative kidney volume for predicting renal function in renal cell carcinoma patients receiving a radical or partial nephrectomy. *BJU Int.* 2012 May;109(10):1468-73.
3. Kayaalp C, Arda K, Oto A, Oran M. Liver volume measurement by spiral CT: an in vitro study. *Clin Imaging.* 2002 Mar-Apr;26(2):122-4.
4. Lim MC, Tan CH, Cai J, Zheng J, Kow AW. CT volumetry of the liver: where does it stand in clinical practice? *Clin Radiol.* 2014 Sep;69(9):887-95.
5. Geraghty EM, Boone JM, McGahan JP, Jain K. Normal organ volume assessment from abdominal CT. *Abdom Imaging.* 2004 Jul-Aug;29(4):482-90.
6. Herts BR, Sharma N, Lieber M, Freire M, Goldfarb DA, Poggio ED. Estimating glomerular filtration rate in kidney donors: a model constructed with renal volume measurements from donor CT scans. *Radiology.* 2009 Jul;252(1):109-16.
7. Hu H. Multi-slice helical CT: scan and reconstruction. *Med Phys.* 1999 Jan;26(1):5-18.
8. Lobacz MA, Sullivan M, Mellor D, Hammond G, Labruyère J, Dennis R. Effect of breed, age, weight and gender on radiographic renal size in the dog. *Vet Radiol Ultrasound.* 2012 Jul-Aug;53(4):437-41.
9. Schwarz T, Saunders J. *Veterinary computed tomography.* John Wiley & Sons, 2011.
10. Schiano TD, Bodian C, Schwartz ME, Glajchen N, Min AD. Accuracy and significance of computed tomographic scan assessment of hepatic volume in patients undergoing liver transplantation. *Transplantation.* 2000 Feb 27;69(4):545-50.
11. Sharma N, O'Hara J, Novick AC, Lieber M, Remer EM, Herts BR. Correlation between loss of renal function and loss of renal volume after partial nephrectomy for tumor in a solitary kidney. *J Urol.* 2008 Apr;179(4):1284-8.
12. Sharma N, Zhang Z, Mir MC, Takagi T, Bullen J, Campbell SC, Remer EM. Comparison of 2 Computed Tomography-based Methods to Estimate Preoperative and Postoperative Renal Parenchymal Volume and Correlation With Functional Changes After Partial Nephrectomy. *Urology.* 2015 Jul;86(1):80-6.
13. Stieger SM, Zwingenberger A, Pollard RE, Kyles AE, Wisner ER. Hepatic volume estimation using quantitative computed tomography in dogs with portosystemic shunts. *Vet Radiol Ultrasound.* 2007 Sep-Oct;48(5):409-13.
14. Thibault JB, Sauer KD, Bouman CA, Hsieh J. A three-dimensional statistical approach to improved image quality for multislice helical CT. *Med Phys.* 2007 Nov;34(11):4526-44.
15. Tyson R, Logsdon SA, Werre SR, Daniel GB. Estimation of feline renal volume using computed tomography and ultrasound. *Vet Radiol Ultrasound.* 2013 Mar-Apr;54(2):127-32.
16. Vali Y, Molazem M. Is feline renal volume related to second lumbar vertebra as well as renal length. *Vet. Radiol. Ultrasound* 2016;57(2):207-12.
17. Zachary JF. *PATHOLOGIC BASIS OF VETERINARY DISEASE.* Elsevier, 2017.