

CASE REPORT

Chromoblastomycosis of the heel with carcinomatous degeneration in a 32 - year - old man

Cromoblastomycosis del talón con degeneración carcinomatosa en un hombre de 32 años

**Fanjalalaina Malinirina Ralahy MD¹ , Joël Razafimahefa MD²,
Tahiriarivelo Randriamanantena MD³, Nomena Randrianarisoa MD⁴,
Rivo Rakotoarivelo PHD⁵, Fahafahantsoa Rabenja Rapelanoro PHD⁶**

1. Service d'orthopédie CHU Tambohobe Fianarantsoa

2. Department of anatomo-pathology CHU Andrainjato

3. Department of maxillofacial surgery CHU Tambohobe Fianarantsoa

4. Service d'orthopédie CHU Fianarantsoa

5. Faculty of Medicine of Fianarantsoa

6. Faculty of Medicine of Antananarivo

Corresponding author

Fanjalalaina Malinirina Ralahy
E-mail: fafah.ralahy@gmail.com

Received: 19 - VIII - 2022

Accepted: 27 - VIII - 2022

doi: 10.3306/AJHS.2022.37.05.165

Abstract

Introduction: Chromoblastomycosis is a wart dermatosis. Madagascar is one of the worst affected countries in the world. Rare sporadic cases of malignant degeneration of chromoblastomycosis have been reported in the literature. This observation reports a case of degeneration of a case of inveterate chromoblastomycosis of the heel.

Observation: This was a 32-year-old young man who consulted for a chronic heel injury on his left foot that progressed for several years. For 8 months, the budding has rapidly increased in size with the appearance of inguinal lymphadenopathy. The lateral heel x-ray showed osteolysis of the greater tuberosity of the calcaneus. A biopsy made it possible to make the diagnosis of squamous cell carcinoma infiltrating chromoblastomycosis. A trans-femoral amputation was performed associated with an inguinal lymph node dissection. At 24 months of follow-up, the patient was in complete remission.

Conclusion: Carcinomatous degeneration is an insidious course and is a dramatic twist in chromoblastomycosis. Radical early treatment with amputation and lymph node dissection can achieve a good result.

Key words: Chromoblastomycosis, heel, osteolysis, squamous cell carcinoma, surgical amputation.

Resumen

Introducción: La cromoblastomycosis es una dermatosis verrugosa. Madagascar es uno de los países más afectados del mundo. Se han informado en la literatura casos esporádicos raros de degeneración maligna de cromoblastomycosis. Esta observación informa de un caso de degeneración de un caso de cromoblastomycosis inveterada del talón.

Observación: Se trata de un joven de 32 años que consulta por una lesión crónica en el talón del pie izquierdo de varios años de evolución. Desde hace 8 meses, la gemación ha aumentado rápidamente de tamaño con la aparición de adenopatías inguinales. La radiografía lateral de talón mostró osteólisis de la tuberosidad mayor del calcáneo. Una biopsia permitió hacer el diagnóstico de cromoblastomycosis infiltrante de carcinoma de células escamosas. Se realizó una amputación transfemorales asociada a una linfadenectomía inguinal. A los 24 meses de seguimiento, el paciente se encontraba en remisión completa.

Conclusión: La degeneración carcinomatosa es un curso insidioso y es un giro dramático en la cromoblastomycosis. El tratamiento temprano radical con amputación y disección de ganglios linfáticos puede lograr un buen resultado.

Palabras clave: Amputación quirúrgica, carcinoma de células escamosas, cromoblastomycosis, talón, osteólisis.

Introduction

Chromoblastomycosis is a manifestation of a fungal cutaneous infection, commonly caused by *Fonsecaea*, *Phialophora*, and *Cladophialophora spp.* *Chromoblastomycosis* is found in tropical and subtropical climate zones, especially in Philippines, Malaysia, Venezuela, India and Brazil. Madagascar represents the most important focus of this fungal disease in the world with one case for every 480 inhabitants¹. The contamination consists of a direct inoculation of the fungus into wounds from contaminated materials. This is almost seen in adults, walking barefoot in rural forest. Occasional sporadic cases of malignant transformation of chromoblastomycosis have been reported in the literature. Herein, we report a case of chromoblastomycosis of the heel with carcinomatous degeneration. The purpose is to provide additional knowledge of this insidious evolution.

Case presentation

A 32 - year - old man presents with a budding wound of the right heel. He works in the tropical forest reserve of the centre - east of Madagascar. Other than a regular artisanal alcoholic consumption, his past medical history was unremarkable.

The disease started 10 years earlier after a wood splinter injury of the left heel in the forest. Despite local wound cares, he noticed a slowly progressive raised lesion in the central zone of the initial wound in an apyretic context. He was then referred to the local health center and underwent 3 surgical excisions during the disease course, respectively 2 years, 2 years and 6 months, 4 years after the initial injury, which were all followed by relapse.

Since 8 months, the budding lesion increased rapidly in size and inguinal lymph nodes were enlarged. He also complained of inflammatory disabling pain over the lesion. The pain was increasingly intense, particularly at night, radiating to the leg and the posterior face of ipsilateral knee.

At presentation, the patient was afebrile, had a performance status score of 4 and the body mass index was 17,9kg/m². A large cauliflower – like lesion that entirely involved the whole posterior part of the right foot has been noticed and measured about 20 cm in diameter. Superficial skin was inflamed and showed collateral circulations (**Figure 1**). An enlarged firm and fixed inguinal lymph node measuring 3 cm in diameter has been also observed. The rest of the physical examination was unremarkable.

Biological evaluation revealed normal blood count results and HIV test result was negative. Radiographs of the left heel in projection profile demonstrated an osteolytic lesion of the calcaneal tuberosity characterized by centripetally disorganized opacities with a superposed wave aspect in the distal margin (**Figure 2**).

A biopsy has been performed between a normal - appearing tissue and the lesion. Histopathological examination revealed an invasive squamous cell carcinoma arising from chromoblastomycosis (**Figure 3**).

Despite the limited availability of imaging, staging procedures only included chest X-ray and abdominal ultrasound that did not perceive any malignant localisation.

The patient underwent a transfemoral amputation with inguinal lymph node dissection. Histopathological

Figure 1: Ulcero-budding heel wound with central fissures and peripheral inflammation.

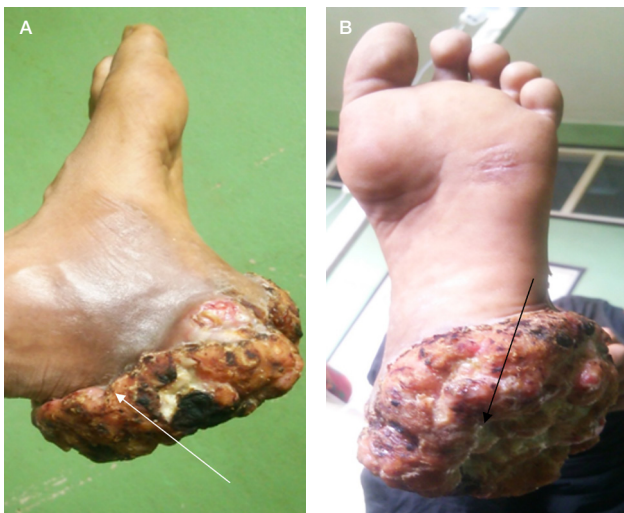

Figure 2: Radiographs of the left heel : osteolytic lesion of the calcaneal tuberosity

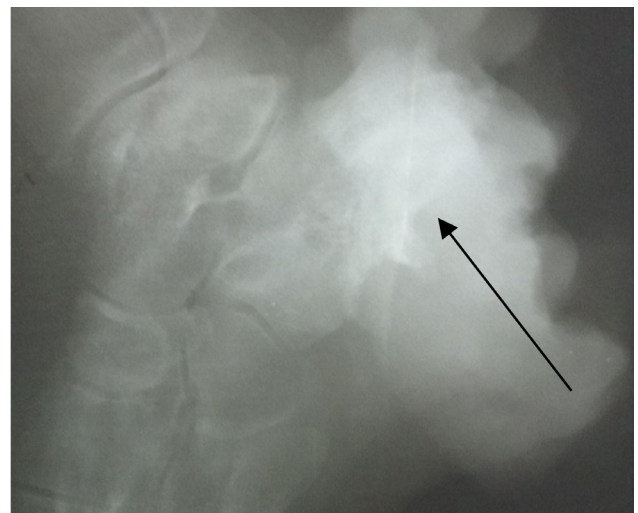
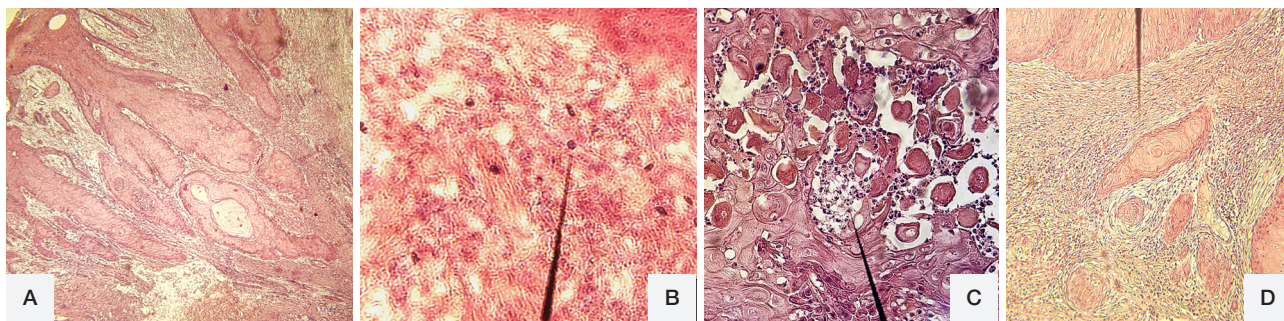


Figure 3: Invasive squamous cell carcinoma arising from chromoblastomycosis.

A, pseudoepitheliomatous hyperplasia. **B**, fumagoid bodies or sclerotic bodies (arrow). **C**, inflammatory cells exocytosis, intraepidermal abscess (arrow). **D**, Malignant transformation, characterized by atypical cells, infiltrating deeply into the dermis. (Hematoxylin Eosin staining x 400)



examination of the surgical specimen confirmed the diagnosis. A total of 24 lymph nodes were examined, among which 3 were metastatic. Based on a multidisciplinary decision, no adjuvant treatment was conducted. At 24 months - follow up, the patient was alive and well with complete remission.

Discussion

The first report of malignant transformation of chromoblastomycosis was described by Caplan in 1968² in a patient from Nicaragua. Since then, 10 other cases have been reported especially in tropical rainforest areas like Brazil and Madagascar. In all those cases, the median age of patients was 63 years old [39 - 72]³. In the present paper, we describe the first case of neoplastic degeneration of chromoblastomycosis in a patient under 35 years of age.

Six species are recognized to cause chromoblastomycosis, which are *Chladophialophora carrionii*, *Fonseca compacta*, *Fonseca pedrosoi*, *Phialophora verrucosa*, *Rhinocladiella aquaspersa* and *Exphiala*⁴. The disease is characterized by the presence of sclerotic bodies or muriform bodies, in infected tissues. In Madagascar, the prevalence rate is among the highest reported in the world and the main causative agents are *Fonseca pedrosoi* and *Chladophialophora carrionii*⁴. Those 2 species have been also mostly implicated in malignant transformation of chromoblastomycosis⁶. In our case, the diagnosis has been made histologically on a biopsy specimen that did not allow isolating the causative agent.

The infection usually results from a traumatic injury and a direct inoculation of the fungus. Thus the foot is the most frequently involved site. The primary lesion is represented by a papule that slowly enlarges and forms a friable and easily bleeding vegetating lesion. However, ulcerated patterns may also be observed. The wound could be secondarily infected with bacteria. Lesions that evolved over 10 years with clinical characteristic changes may suggest a malignant degeneration. In our

case, the pain exacerbation and the presence of new lesions with ulcerated pattern on the primary lesion have motivated the patient to consult. Carcinomatous degeneration of chromoblastomycosis is included among malignant transformation of chronic wounds of infectious (paracoccidioidomycosis, leishmaniasis, lobomycosis, tropical ulcers and chronic osteomyelitis) or traumatic (burn scars, traumatic wounds) causes. Malignant transformation usually occurs more than 10 years after the primary lesion. It has been reported that chronic inflammation produces cytotoxic molecules (leukotrienes, prostaglandins) and free radicals which may induce nuclear alterations and activate or increase oncogene expressions⁷. Besides, prolonged local Voriconazole therapy is also associated with a high risk of malignant transformation⁸. The most common histologic type is squamous cell carcinoma. Malignant melanoma has been also described in rare cases⁶. Evolution is almost always favorable after surgery, except in the presence of visceral metastasis. Amputation is usually required as extensive local and regional spread is mostly encountered. This has been observed in our cases and transfemoral amputation with inguinal lymph node dissection has been performed. To prevent the possibility of malignant transformation as well as to avoid amputation, the disease should be early – treated. The combination of antifungal drugs with immunoadjuvant compounds such as glucan and imiquimod have been investigated in recent years. The glucan, which is an immunomodulator, is considered as an effective treatment, in injectable formulation and associated with itraconazole⁶. Imiquimod, an immunomodulatory agent that exhibits antitumor and antiviral effects, is also effective in external use, 4 times a week and combined with itraconazole⁹. There are also data to suggest that terbinafine, initially used by Esterre et al¹⁰, is effective in conjunction with amphotericin B, and some other therapeutic approaches such as surgery, phototherapy and CO₂ laser. However, the real challenge for countries with a fragile health system like Madagascar is to ensure early diagnosis and access to treatment.

Conclusion

Carcinomatous degeneration is an insidious and dramatic progression of the lesions of Chromoblastomycosis. Early treatment represented by radical amputation associated with lymph node dissection showed good results.

Conflict of interest

Authors do not have any conflict of interest to declare.

Bibliography

1. Torres E, Beristain JG, Lievanos Z, Arenas R. Chromoblastomycosis associated with a lethal squamous cell carcinoma. *An Bras Dermatol*. 2010 ; 85(2) : 267-70.
2. Caplan RM. Epidermoid carcinoma arising in extensive chromoblastomycosis. *Arch Dermatol*. 1968; 97(1);38-41.
3. Azevedo CMPS, Marques SG, Santos DWC, Silva RR, Silva NF, Santos AS et al. Squamous cell carcinoma derived from chronic chromoblastomycosis in Brazil. *Clin Infect Dis*. 2015; 60(10):1500- 4.
4. Momin YA, Raghuvanshi SR, Lanjewar DN. Cutaneous chromoblastomycosis. *Bombay Hosp J* 2008; 50: 299-301.
5. Queiroz-Telles F, Sybren de Hoog , Santos DWCL, Salgado CG, Vicente VA, Bonifaz A. Chromoblastomycosis. *Clin Microbiol Rev*2017; 30(1): 233-76.
6. Azevedo Cde M, Marques SG, Resende MA, Gonçalves AG, Santos DV, da Silva RR, et al. The use of glucan as immunostimulant in the treatment of a severe case of chromoblastomycosis. *Mycoses*. 2008; 51: 341-4.
7. Schottenfeld D, Beebe-Dimmer J. Chronic inflammation: a common and important factor in the pathogenesis of neoplasia. *CA Cancer J Clin* 2006; 56:69-83.
8. Williams K, Mansh M, Chin-Hong P, Singer J, Arron ST. Voriconazole-associated cutaneous malignancy: a literature review on photocarcinogenesis in organ transplant recipients. *Clin Infect Dis* 2014; 58:997-1002.
9. de Sousa Mda G, Belda W Jr, Spina R, Lota PR, Valente NS, Brown GD, et al. Topical application of imiquimod as a treatment for Chromoblastomycosis. *Clin Infect Dis*. 2014; 58: 1734-7.
10. Esterre P, Inzan CK, Ramarcel ER, Andriantsimahavandy A, Ratsioharana M, Pecarrere JL, Roig P. Treatment of chromomycosis with terbinafine: preliminary results of an open pilot study. *Br J Dermatol*. 1996; 46: 33-6.