

## ESTUDI DE CASOS

# Conservative Surgical Management with Triple P procedure for the Placenta Accreta with Cervical Invasion: Case report

*Manejo quirúrgico conservador con procedimiento Triple P para la placenta acreta con invasión cervical: reporte de caso*

**Maame Benko<sup>1</sup>, Miriam Crespo Rodríguez<sup>2</sup>, Edwin Chandraharan<sup>3</sup>**

1. Medical Student at St. George's University Hospitals NHS Foundation Trust, London, UK

2. Department of Obstetrics and Gynaecology of University Hospital Son Espases, Palma de Mallorca, Spain

3. Department of Obstetrics and Gynaecology of St. George's University Hospitals NHS Foundation Trust, London, UK

**Correspondencia**

Miriam Crespo Rodríguez

Bonaire p6 2-1 Palma de Mallorca, Baleares. España

E-mail: mcrespo013@gmail.com

**Recibido:** 25 -VI - 2020

**Aceptado:** 28 - VII - 2020

doi: 10.3306/MEDICINABALEAR.35.03.39

**Abstract**

Placenta accreta is an abnormal invasion of the placenta into the uterine myometrium that carries a significant obstetric risk including major post-partum haemorrhages. Unfortunately, this incidence of this condition is on a rise and appears to be linked to the increase in invasive surgical procedures such as caesarean sections, myomectomies and uterine dilatation and curettage, amongst many others. It is in the best interest of women to agree on the most effective management, as it is significantly associated with a non-negligible maternal foetal morbidity and mortality and its incidence is set to increase further. Several management techniques have been proposed and trailed globally with variable evidence on the efficacy of said treatments and variable patient outcomes, yet an optimal management technique is yet to be discovered. We report the case of a 24 year old Gravid 5 Para 4 with a previous history of gestational diabetes, the patients BMI and extensive obstetric history including a shoulder dystocia, Post-Partum haemorrhage and previous placental praevia. In her current pregnancy, a diagnosis of placenta praevia and placenta accreta with evidence of cervical invasion is made and the patient is successfully managed with the novel conservative management surgical 'Triple P' procedure.

**Keywords:** Triple P procedure, placenta accrete, obstetric pathology.

**Resumen**

La placenta accreta es una invasión anormal de la placenta en el miometrio que conlleva un riesgo obstétrico significativo. Desafortunadamente, la incidencia de esta afección está en aumento y parece estar relacionada con el aumento de los procedimientos quirúrgicos invasivos, como cesáreas, miomectomías y legrado uterino, entre muchos otros. Debido a su asociación con una morbilidad y mortalidad fetal materna no despreciable, realizar un manejo efectivo resulta de gran importancia. Se han propuesto y seguido varias técnicas de manejo a nivel mundial con evidencia variable sobre la eficacia de dichos tratamientos, sin embargo, aún no se ha descubierto una técnica de manejo óptima. Presentamos el caso de una paciente con 4 partos previos de 24 años de edad con historial obstétrico extenso que incluye distocia de hombros, hemorragia posparto y praevia placentaria previa. En su embarazo actual, se realiza un diagnóstico de placenta previa acreta con evidencia de invasión cervical y la paciente se maneja con éxito con el novedoso tratamiento quirúrgico conservador denominado "Triple P".

**Palabras clave:** Procedimiento Triple P, placenta ácreta, patología obstétrica.

## Background

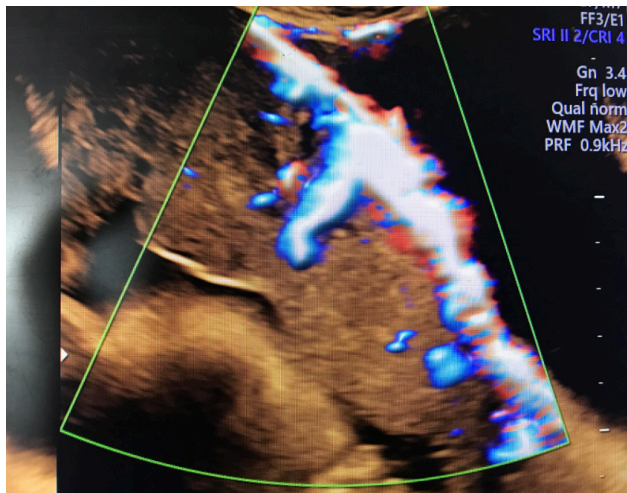
Placenta accreta is an abnormal invasion of the trophoblastic tissue into the myometrium<sup>1</sup>. The incidence of this abnormal placentation has increased in the last decade, from roughly 1 in 2000 to 1 in 500<sup>2</sup>. This is of great importance since this pathology leads to a significant increase in both maternal and fetal morbidity and mortality<sup>6</sup>.

The management of this potentially life threatening condition includes a postpartum hysterectomy, considered by many as the first line treatment<sup>4,5</sup>, or conservative management (intentional retention of the placenta or IRP), where the entire placenta is left in-situ with uterine preservation or partial placental resection, preserving the uterus. A new novel conservative surgical procedure was developed at St George's Hospital, London in 2010 called the Triple P Procedure.

## Objective

Case presentation of conservative surgical management in a pregnant with the prenatal diagnosis of an abnormal placentation (placenta accreta) by antenatal ultrasound (**Figure 1**).

**Figure 1:** Ultrasound performed prior to the intervention where it is observed a disruption of the bladder line and an abnormal vascularity with a thin myometrium.



## Case Report

We report the case of a 24 year old Gravida 5 Para 4 with a previous history of gestational diabetes, the patients BMI and extensive obstetric history including a shoulder dystocia, Post-Partum haemorrhage and previous placental praevia that required an elective caesarean section. In addition, she had a history of deep vein thrombosis and pulmonary embolism during her last pregnancy, for which she was receiving thromboprophylaxis.

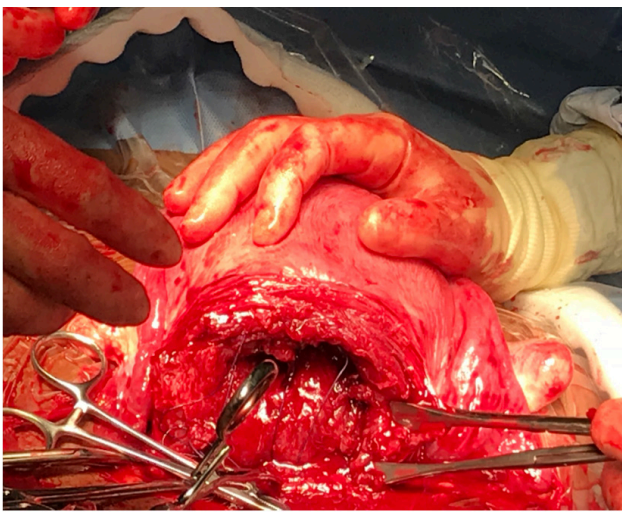
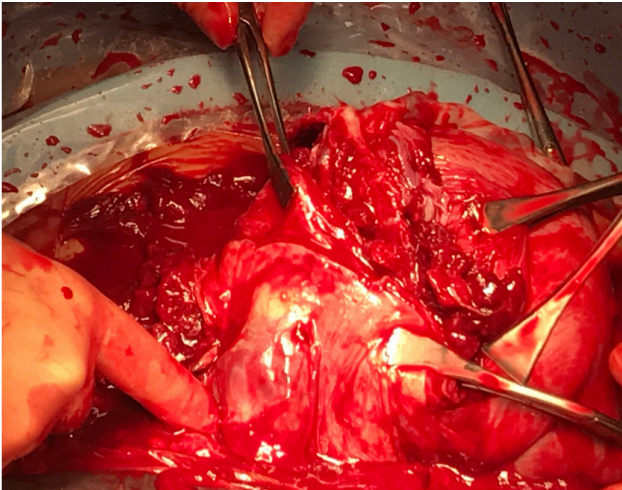
In the current pregnancy, at 27 weeks pregnant the patient was rushed to a District general hospital with a sudden onset of per vaginal bleeding and an estimated blood loss of around 600ml and no associated symptoms. Given the volume of the patients antepartum haemorrhage she was soon transferred to another DGH (Watford) with a specialist unit and a diagnosis of Placenta Praevia with accreta was soon made. An ultrasound was conducted which revealed an echogenic area between the placenta and the internal os suggesting an abnormal placental invasion of the lower uterus. They also found an increased placental thickness, abnormal vessels and the loss of zone. A repeated scan two days later, found identical placental features triggering a referral and transfer to St Georges University Hospital for a more specific diagnosis of placenta accreta for conservative management with an elective Triple P Procedure, booked for 34 weeks gestation for allow for the maturation of the foetus. In total 900ml of blood was lost during her various admissions into hospital.

As described above the success of Triple P procedure owes to the number of pre-surgical measures that are taken to prevent major post-partum haemorrhage. The patient's journey began with the insertion of an epidural, as insertion may be complicated after the insertion of the arterial occlusive balloon. The patient was taken down to interventional radiology for the insertion of arterial balloons into both internal iliac arteries.

The patient entered obstetric theatres at 11:50 am. A transverse uterine incision was made above the upper edge of the placenta to enable the delivery of a live but floppy male infant in a 'frank-breech' presentation. The Pre-inserted balloons were inflated to decrease the volume of intraoperative bleeding. Intraoperatively there was evidence of placental infiltration of the anterior uterine wall with abnormal blood vessel invasion into the myometrium with cervical invasion (**Figure 2**). Following the removal of the non-separated placenta and affected myometrial site there was profuse bleeding from the excision site (**Figure 2**) particularly the anterior cervix necessitating the application of the hemostatic powder, perclot, and trans-uterine insertion of a Bakri balloon tamponade fixated using the vertical sandwich technique. As per the procedure, 3 cm of placental tissue invading the lower cervix was left to facilitate the repair of the myometrial defect. A pre-consented sterilisation was conducted and there was subsequent two-layer reconstruction of the uterine wall. The rest of the intervention was uneventful. The estimated total blood loss during the intervention was 3 liters and one 1 unit of blood products and 200ml of blood recycled through a cell salvage was infused intraoperatively.

A child of 2,360g was born Apgar 1/9 at one minute and 5/9 at 5 minutes, an arterial ph 7.3, venous ph 7.3, a PCO2 6.4 and base excess -2.3. The newborn after

**Figure 2:** Images obtained during surgery that show abnormal placental invasion and excision performed.



birth required ventilation but did not require admission to the neonatal care unit.

The patient's post-operative plan consisted of a 24-hour intravenous infusion of Augmentin (Co-amoxiclav) switched for orally for 5 days, deflation of the arterial balloons after 4 hours with intermittent flushing every 10 minutes and removal of the Bakri balloon tamponade 24 hours after the procedure. Full blood count, clotting and serum B-HCG levels were monitored during her 5-day post-operative and a follow-up appointment for transvaginal ultrasound and repeated serum B-hCG at 6 weeks. She was then discharged on day 5 with no further complications.

## Discussion

Although the pathology of the placenta accreta has been widely studied and described, there are no randomized studies and there are only few articles that discuss its optimal management, with there being wide international

and national variation in what is deemed optimal.

The literature remains divided with some clinicians being in favour of performing a postpartum hysterectomy<sup>7-9</sup> given the serious complications that this pathology can have, such as massive peripartum haemorrhage and the increase in morbidity and mortality. This however may lead to distressing psychological and physical symptoms in the women and also risks pelvic organ injury, particularly ureteric and bladder.

On the other hand, there are several articles that support the conduct of conservative management. The use of the aforementioned surgical measure has been associated with a large percentage of both short and long term complications being described. In one study a postoperative rate of 53% for massive postpartum haemorrhage in patients and 19% often required a postpartum haemorrhage<sup>10</sup>. Many additional complications including sepsis were also described<sup>10</sup>. Given the significant risk of postpartum complications it may be suggested that this should be attempted only rarely, in fully informed patients, as part of approved clinical trials or in hospitals with sufficient resources to support these women postnatally. This is consistent with an opinion of the Committee of the American College of Obstetricians and Gynaecologists.

Another and more recent type of conservative surgical procedure described in the literature involving non-separative placental resection and uterine salvage is known as the Triple P Procedure. This procedure was first described by St Georges university Hospital Trust, London namely by Mr. Chandrabaran, and is the procedure described in our case. The Triple P Procedure consists of the preoperative location of the placenta and the extraction of the fetus by means of a transverse incision at the upper edge of the placenta, pelvic devascularization and the excision of the non-separated placenta and myometrium as one segment. Subsequently, the uterine wall is reconstructed<sup>11, 13</sup>.

At present there are only few published cases that demonstrate the success of this procedure although this is being increasing as more hospitals adopt this management protocol. The most recently published retrospective study, found that within a 7 year period (2010-2017), 50 patients have been operated using this technique and of these patients the average blood loss was 2318 mL, bladder injuries occurred in 2% and there were no injuries to the ureters over this period. The average stay of the patients postoperatively was 4 days with 3 patients developing arterial thrombosis without any long-term complications or the need for secondary hysterectomies. This article, apart from describing the outcomes, mentions, within the tactics to reduce intraoperative and postoperative bleeding, the placement of an intracervical balloon with two vertical



uterine compressive sutures above the balloon could be beneficial for those patients where the placental invasion affects the cervix<sup>12</sup>.

Similarly, a Chinese centre using a modified version of this procedure involving uterine strangulation as opposed to intra-arterial occlusive balloons found a comparable mean blood loss of 2423mL<sup>14</sup>.

This procedure strategy, apart from the advantage of preserving the uterus, seems to reduce intraoperative blood loss, decrease hospital stay and suppose a lower hospital cost<sup>12, 14</sup>.

## Conclusion

The conservative management of the placenta accreta, specifically the Triple P procedure is a procedure highly centered on uterine salvage and the reduction of postoperative mortality and morbidity by essential collaborative preoperative planning. Despite the small number of cases described, there is increasing evidence to demonstrate its effectiveness and seems to so far be a safe alternative to conservative surgical management, given its tendency to reduce both short and long term peripartum complications. The optimal management of placenta abnormal implantation still remains an

unanswered question in the obstetric community and as with many things in medicine randomised research is still required and frequent case analysis must be conducted to ensure that the potential for effective management can be achieved one day.

## Disclosure of interests

Full disclosure of interests available to view online as supporting information.

## Contribution to authorship

All individuals that qualified for authorship have been included and all those included qualify for authorship. Miriam Crespo and Maame Benko contributed to conception and design, interpreted the data and drafted the article. Edwin Chandaharan was the reviewer of the article and one of the surgeons in the intervention described. All authors revised the article critically for intellectual content and approved the final version to be published.

## Details of ethics approval

The patient gave verbal and written informed consent for this report, which conforms to the ethical guidelines of the Helsinki Declaration of 1975.

## Funding

None.

## Acknowledgements

We thank all the Obstetrics team of St Georges University Hospital, and also to the patient, for allowing us to share her case.

## References

1. Shamshirsaz AA, Fox KA, Salmanian B, et al. Maternal morbidity in patients with morbidly adherent placenta treated with and without standardized multidisciplinary approach. *Am J Obstet Gynecol* 2015; 212:218. e1-9.
2. Pinas-Carrillo A, Chandaharan E. 2016. Management of morbidly adherent placenta. *Obstetrics, Gynaecology & Reproductive Medicine* 26:283-90.
3. Teixidor Viñas M, Belli AM, Arulkumaran S, Chandaharan E. Prevention of postpartum haemorrhage and hysterectomy in patients with morbidly adherent placenta: a cohort study comparing outcomes before and after introduction of the Triple-P procedure. *Ultrasound Obstet Gynecol*. 2015 Sep; 46(3):350-5.
4. Eller AG, Porter TF, Soisson P, Silver RM. Optimal management strategies for placenta accreta. *BJOG*. 2009; 116(5):648. Epub 2009 Feb 4.
5. Wong HS, Hutton J, Zuccollo J, Tait J, Pringle KC. The maternal outcome in placenta accreta: the significance of antenatal diagnosis and non-separation of placenta at delivery. *N Z Med J*. 2008; 121(1277):30.
6. Chan BC, Lam HS, Yuen JH, et al. Conservative management of placenta praevia with accreta. *Hong Kong Med J* 2008; 14(06):479-84
7. Obstetric Care Consensus No. 7: Placenta Accreta Spectrum. *Obstet Gynecol* 2018; 132:e259.
8. Eller AG, Porter TF, Soisson P, Silver RM. Optimal management strategies for placenta accreta. *BJOG* 2009; 116:648.
9. Oyelese Y, Smulian JC. Placenta previa, placenta accreta, and vasa previa. *Obstet Gynecol* 2006; 107:927.
10. Steins Bisschop CN, Schaap TP, Vogelvang TE, Scholten PC. Invasive placentation and uterus preserving treatment modalities: a systematic review. *Arch Gynecol Obstet* 2011; 284:491.
11. Teixidor Viñas M, Belli AM, Arulkumaran S, Chandaharan E. Prevention of postpartum haemorrhage and hysterectomy in patients with morbidly adherent placenta: a cohort study comparing outcomes before and after introduction of the Triple-P procedure. *Ultrasound Obstet Gynecol* 2015; 46:350.
12. Piñas-Carrillo A, Bhide A, Moore J, Hartopp R, Belli AM, Arulkumaran S, Thilaganathan B, Chandaharan E. Outcomes of the first 50 patients with abnormally invasive placenta managed using the "Triple P Procedure" conservative surgical approach. *IJGO*. 2019.
13. Chandaharan E, Rao S, Belli AM, Arulkumaran S. The Triple-P Procedure as a conservative surgical alternative to peripartum hysterectomy for placenta percreta. *Int J Gynaecol Obstet*. 2012 May; 117(2):191-4.
14. Wei Y, Cao Y, Yu Y, et al. Evaluation of a modified 'Triple-P' procedure in women with morbidly adherent placenta after previous caesarean section. *Arch Gynecol Obstet* 2017; 296(4): 737-43.
15. Obstetric Care Consensus No. 7: Placenta Accreta Spectrum. *Obstet Gynecol* 2018; 132:e259.